Role of Cilia and Left-Right Patterning in Congenital Heart Disease

8

Nikolai Klena, George Gabriel, Xiaoqin Liu, Hisato Yagi, You Li, Yu Chen, Maliha Zahid, Kimimasa Tobita, Linda Leatherbury, Gregory Pazour, and Cecilia W. Lo

Abstract

A central role for cilia in the pathogenesis of congenital heart disease was uncovered by our large-scale mouse mutagenesis screen for mutations causing congenital heart disease. This is supported by human clinical studies, which showed a high prevalence of ciliary dysfunction and respiratory symptoms and disease in patients with congenital heart disease. Our mouse studies indicate this involves essential roles for both primary and motile cilia in the pathogenesis of congenital heart disease. As laterality defects were also observed with high prevalence among the congenital heart disease mutants, this further suggested an important role for left-right patterning in the pathogenesis of congenital heart disease. This finding is reminiscent of the high prevalence of heterotaxy among human fetuses with congenital heart disease, indicating the fetal mouse screen may provide a window into the unborn human fetal population. Clinically, congenital heart disease patients with ciliary dysfunction were found to have more respiratory symptoms and disease, a finding with significant clinical implications, as congenital heart disease patients undergoing surgical palliation often have respiratory complications with high morbidity. While this is usually attributed to the heart disease, we propose this may involve intrinsic airway clearance deficits from ciliary dysfunction. Thus the presurgical screening of congenital heart disease patients for respiratory ciliary dysfunction may provide

N. Klena • G. Gabriel • X. Liu • H. Yagi • Y. Li • Y. Chen • M. Zahid • K. Tobita • C.W. Lo (✉)
Department of Developmental Biology, University of Pittsburgh School of Medicine, Pittsburgh, PA 15201, USA
e-mail: cel36@pitt.edu

L. Leatherbury
Children's National Medical Center, Washington, DC, USA

G. Pazour
Program in Molecular Medicine, University of Massachusetts Medical School, Worcester, MA, USA

© The Author(s) 2016

T. Nakanishi et al. (eds.), *Etiology and Morphogenesis of Congenital Heart Disease*,
DOI 10.1007/978-4-431-54628-3_8

opportunities to provide perioperative pulmonary therapy to enhance airway clearance for at-risk patients. Such change in the standard of care may improve outcome, especially for those congenital heart disease patients who must endure multiple rounds of cardiac surgeries.

Keywords
Cilia • Ciliary dysfunction • Respiratory symptoms • Laterality • Heterotaxy

8.1 Introduction

Complex congenital heart disease is clinically well described to be highly associated with heterotaxy, a birth defect involving randomization of left-right patterning [1]. The importance of left-right patterning in congenital heart disease is likely a reflection of the fact that the heart is the most left-right asymmetric organ in the body. This asymmetry is critical for establishing systemic and pulmonary circulation required for efficient oxygenation of blood. While heterotaxy is relatively rare, reported at approximately 1 in 10,000 live births, it is clinically of high importance given it is often associated with complex CHD with high morbidity and mortality [2].

8.1.1 Heterotaxy, Primary Ciliary Dyskinesia, and Motile Cilia Defects

Interestingly, heterotaxy and complex CHD have been reported in ~6 % of patients with primary ciliary dyskinesia (PCD), a sinopulmonary disease that arises from airway mucus clearance defects due to immotile or dyskinetic cilia in the respiratory epithelia [3]. Given PCD is also relatively rare at 1 in 16,000 [4], the co-occurrence of heterotaxy and PCD would suggest a mechanistic link for heterotaxy and PCD. This mechanistic link has now been demonstrated to involve a shared disturbance of motile function. Thus animal model studies have shown motile cilia play an important role in embryonic left-right patterning [5].

In the mouse embryo, motile cilia at the node generate nodal flow that helps specify the left-right axis (Fig. 8.1). The nodal flow is sensed by nonmotile or primary cilia at the node periphery, resulting in activation of calcium signaling at the embryo's left, followed by left-sided activation of the nodal signaling cascade in the left lateral plate mesoderm. As motile cilia in the node and airway are constructed in a similar manner with many of the same proteins, it is not surprising that airway ciliary dysfunction might predict nodal cilia dysfunction. This likely accounts for the high prevalence of heterotaxy among PCD patients.

8.1.2 Motile Respiratory Cilia Defects in Other Ciliopathies

Given primary cilia also has been shown to play a role in the embryonic node to establish the left-right axis, this would suggest that mutations affecting primary

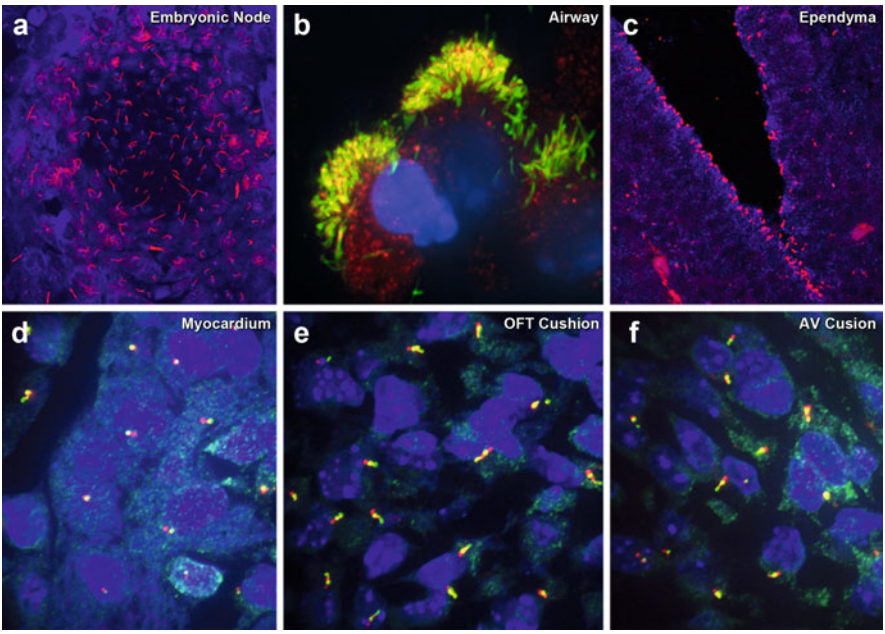

Fig. 8.1 Motile and primary cilia in the mouse embryo. (**a**) Immunostaining with antibodies to acetylated tubulin (*red*) and γ-tubulin (*blue*) was used to visualize motile cilia in the E7.75 mouse embryonic node. (**b**–**f**) Immunostaining with antibodies to acetylated tubulin and IFT88 visualized cilia in the newborn mouse tracheal airway epithelia (**b**), in E12.5 brain ependyma (**c**), and primary cilia in the myocardium (**d**), outflow tract cushion (**e**), and atrioventricular cushion (**f**) of the E12.5 mouse embryonic heart

cilia function may also contribute to complex CHD associated with heterotaxy. Given the extensive overlap between proteins found in the primary and motile cilia, this would suggest the clinical distinction may be blurred between patients with ciliopathies considered mediated by primary cilia defects vs. those with PCD that have motile cilia defects. Indeed in a recent study, we showed that a patient with cranioectodermal dysplasia, a ciliopathy thought to involve the primary cilia, has presentations consistent with PCD. This includes obstructive airway disease, low nasal NO, and abnormal respiratory ciliary motion [6].

8.1.3 Ciliary Dysfunction in Congenital Heart Disease Patients with Heterotaxy

Even as PCD patients were observed to have a 6 % incidence of heterotaxy, a study of CHD patients with heterotaxy revealed an even higher prevalence of respiratory ciliary dysfunction similar to that seen with PCD [7]. Two tests used for PCD assessment were used to evaluate heterotaxy patients. Ciliary motion analyzed

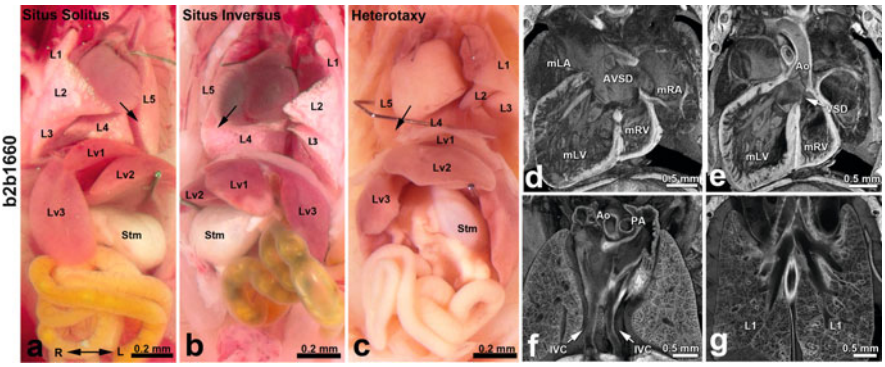

Fig. 8.2 Situs anomalies, congenital heart defects and ciliogenesis defects in laterality mutants. (**a**–**g**) *Ap1b1*^{b2b1660} mutants exhibit situs solitus (**a**), situs inversus (**b**), or heterotaxy (**c**). Situs solitus, characterized by normal left-right visceral organ positioning, the heart apex (*arrow*) points to the left (levocardia), four lung lobes are on the right and one on the left, stomach is to the left, and the dominant liver lobe is on the right. With situs inversus, there is complete mirror reversal of organ situs, while with heterotaxy, visceral organ situs is randomized, such as dextrocardia with levogastria shown in (**c**). The heterotaxy mutant in (**c**) exhibit complex CHD with AVSD (**d**), ventricular septal defect (VSD) (**e**), duplicated inferior vena cava (IVC) (**f**), and left pulmonary isomerism with bilateral single lung lobes (**g**) (From Li et al. [11])

using videomicroscopy of nasal tissue biopsy and nasal nitric oxide (nNO) was measured, which is typically low in patients with PCD. This analysis showed 42 % of the heterotaxy patients have ciliary dysfunction comprising abnormal ciliary motion and low nNO, presentations typically seen with PCD [7].

Interestingly, a mouse mutant exhibiting complex congenital heart defect associated with heterotaxy was identified to have a pathogenic mutation in *Dnah5*, a cilium outer dynein arm component required for motile cilia function and a gene well described to cause PCD [8]. This mutant exhibited mostly immotile cilia in the airway and in the embryonic node [8], accounting for the laterality disturbance and airway clearance defects seen in PCD patients with *DNAH5* mutations. Interestingly, these *Dnah5* mutant mice exhibited either of three different laterality phenotypes: normal situs solitus, mirror symmetric situs inversus totalis, or randomized visceral organ situs known as heterotaxy (Fig. 8.2). It is only with heterotaxy that complex congenital heart disease was observed, indicating that disturbance of the left-right patterning may play an important role in congenital heart disease. As the mouse *Dnah5* mutants with heterotaxy were mostly inviable to term due to their complex congenital heart disease, this would suggest considerable ascertainment bias in the human population. Consistent with this, a study of PCD patients revealed most had either situs solitus or situs inversus, with only a small fraction exhibiting heterotaxy [4].

8.1.4 Respiratory Complications in Heterotaxy Patients with Ciliary Dysfunction

As the central hallmark of PCD is respiratory disease due to mucociliary clearance defects, the question arises as to whether heterotaxy patients may also have respiratory symptoms and disease. Indeed, heterotaxy patients with ciliary dysfunction are observed to have significantly more respiratory symptoms and disease [7]. Furthermore, those undergoing surgical procedures show increased pulmonary morbidity, including increased use of inhaled β-agonist [9]. β-agonist use is typically avoided in cardiac patients given its arrhythmogenic properties. Hence, the increased use of this medication is a strong indicator of serious respiratory complications.

These findings have important clinical translational ramifications, since respiratory complications in heterotaxy patients are usually attributed to the heart disease, and thus any airway clearance defects are not systematically addressed clinically. In light of these findings, a change in the standard of care may be warranted with the presurgical screening of heterotaxy patients for mucociliary clearance defects and providing airway clearance therapy to help reduce postsurgical respiratory complications in those with airway ciliary dysfunction. This may help improve the prognosis for these patients who typically have to endure multiple high-risk cardiac surgeries to palliate their structural heart defects.

8.1.5 Left-Right Patterning and the Pathogenesis of Congenital Heart Disease

The importance of left-right patterning in the pathogenesis of congenital heart disease has also emerged from a large-scale mouse mutagenesis screen. High-throughput screening of ENU-mutagenized mice using fetal echocardiography allowed the ultrasound phenotyping of greater than 80,000 fetuses (Fig. 8.3) [10, 11]. Fetal echocardiography is ideally suited for recovery of mutants with congenital heart defects, as it is an imaging modality developed in the clinical setting for the assessment of cardiac structure and function (Fig. 8.3). Over 200 mutant mouse lines with a wide spectrum of congenital heart defect were recovered. Surprisingly, this included many mutant lines with laterality defects (~30 %), recovered based on the finding of complex CHD in mutants with heterotaxy. Given our screen was focused on congenital heart defects, not left-right patterning defects, this enrichment of laterality mutants would suggest the disturbance of left-right patterning plays an important role in the pathogenesis of congenital heart disease.

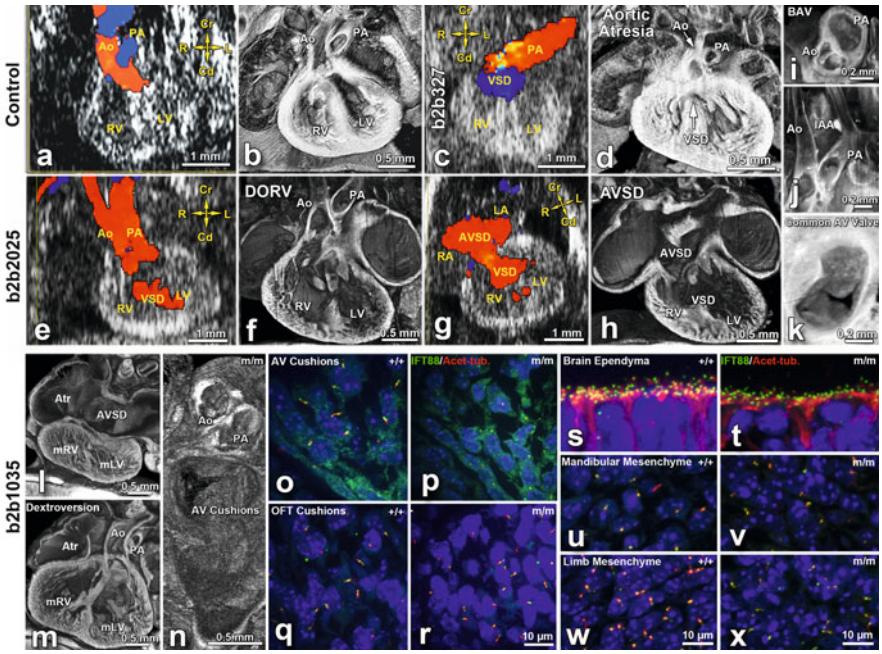

Fig. 8.3 Ultrasound diagnoses of congenital heart disease and cilia defects in mouse mutants with congenital heart disease. Vevo 2100 color flow imaging showed crisscrossing of blood flow, indicating normal aorta (Ao) and pulmonary artery (PA) alignment (**a** Supplemental Movie S1), confirmed by histopathology (**b**). E16.5 mutant (line b2b327) exhibited blood flow pattern indicating single great artery (PA) and ventricular septal defect (VSD) (**c** Supplemental Movie S2), suggesting aortic atresia with VSD, confirmed by histopathology (**d**). Color flow imaging of E15.5 mutant (line b2b2025) with heterotaxy (stomach on right; Supplemental Movie S3c) had side-by-side Ao/PA with Ao emerging from the right ventricle (RV), indicating DORV/VSD (**e**, **f** Supplemental Movie S3a) and presence of AVSD (**g**, **h** Supplemental Movie S3b,S3c). Histopathology also showed bicuspid aortic valve (BAV, **i**), interrupted aortic arch (IAA, **j**), and common AV valve (**k**). (**l**–**n**) *Cc2d2a* mutant exhibits dextrocardia with ventricular inversion (dextroversion) (**m**) and AVSD (**l**) with malformed AV cushions (**n**) but normal outflow cushions. (**o**–**x**) Confocal imaging of E12.5 *Cc2d2a* mutant (m/m) vs. wild-type (+/+) embryo sections showed no cilia in AV cushion (**o**, **p**) but normal ciliation in outflow cushion (**q**, **r**). Fewer and shorter cilia were observed in other mutant embryo tissues (**s**–**x**). *Red*, acetylated tubulin; *green*, IFT88 (From Li et al. [11])

This unexpected finding of a high prevalence of heterotaxy is actually in line with observations in the human fetal population. One clinical study using fetal echocardiography for CHD diagnosis reported that 16 % of human fetuses with congenital heart defects have heterotaxy [12]. This number is likely a minimal estimate, given several clinical studies have shown human fetuses with heterotaxy

and congenital heart defect have very high rates of prenatal/intrauterine death (30–60 %) [13–15]. When combined with the fact that only 28 % of CHD is clinically diagnosed prenatally [16], these findings point to the prevalence of congenital heart disease associated with heterotaxy being significantly underestimated clinically. In our mouse screen, we also noted most mouse fetuses with congenital heart defects associated with heterotaxy died in utero. The recovery of these heterotaxy mutants rests entirely on our screen having been conducted prenatally with fetal ultrasound imaging.

Of importance to note is the fact that many of these mutant lines with heterotaxy actually yielded three distinct phenotypes, similar to what had been observed for the *Dnah5* mutants. Thus animals harboring the same mutation can have normal situs solitus, mirror symmetric situs inversus, or heterotaxy (Fig. 8.2). As with the *Dnah5* mutants, congenital heart defects were usually seen only in mutants with heterotaxy [11]. In a subset of these mutants, videomicroscopy of the tracheal epithelia in these mutants also showed immotile or dyskinetic cilia, suggesting they have mutations affecting motile cilia function and may be PCD mouse models [11].

8.1.6 Ciliome Gene Enrichment Among Mutations Causing Congenital Heart Disease

Whole-mouse exome-sequencing analysis was used to recover the pathogenic CHD-causing mutations in mutants recovered from the large-scale mouse mutagenesis screen. This was made possible given the screen was conducted in a C57BL6 inbred strain background. From this analysis, 91 pathogenic mutations were recovered in 61 genes (Fig. 8.4). Of the 61 genes, 35 (58 %) are in cilia-related or ciliome genes (Fig. 8.5); this included 12 genes (34 %) required for motile cilia function (Fig. 8.4). Indeed 8 of these genes are known to cause PCD, including many alleles of *Dnah5* and *Dnah11* (Fig. 8.5). Interestingly, 23 of the cilia genes are actually primary cilia related (66 %). Of these, half are found in mutant lines with laterality defects and half in lines without laterality defects (Fig. 8.4) [11]. These findings suggest the link between cilia and CHD is broader, not merely a reflection of the role of cilia in left-right patterning. This is further supported by the recovery of 15 pathogenic mutations in genes involved in cilia-transduced cell signaling, including mutations in genes involved in Shh, Wnt, Tgfβ, and calcium signaling (Fig. 8.5), all pathways known to play important role in cardiovascular development [11].

Relevant to this, we note cilia is broadly expressed in the embryonic heart, including in the atrial and ventricular myocardium, the atrioventricular and outflow endocardial cushions (Fig. 8.1d–f). Importantly, in the *Cc2d2a* mutant recovered

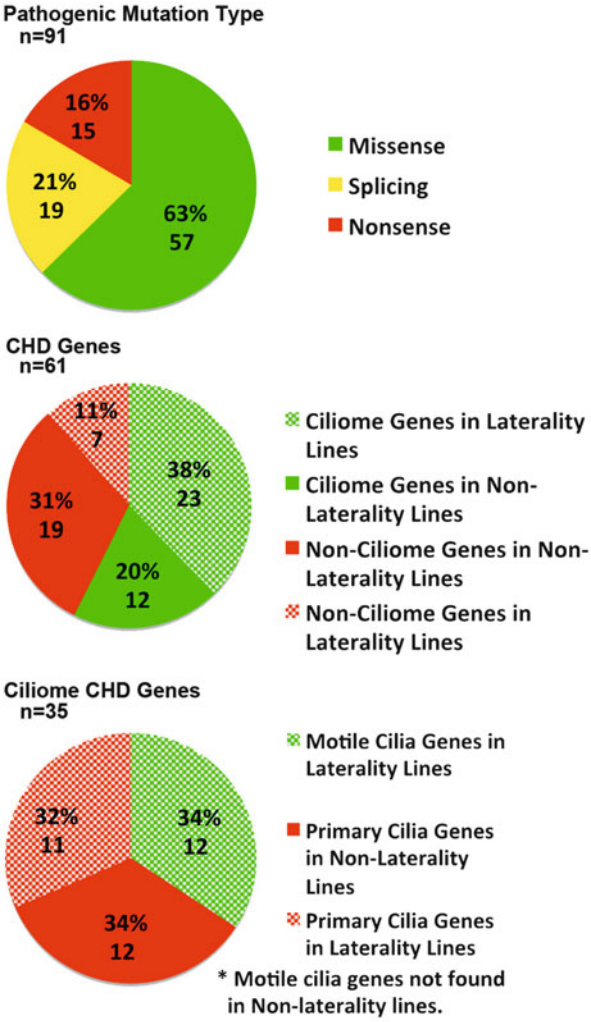

Fig. 8.4 Distribution of pathogenic congenital heart disease causing mutations recovered from large-scale mouse forward genetic screen**.** *Top*: Distribution of pathogenic CHD mutations among different mutation types. *Middle*: Ciliome vs. non-ciliome CHD genes found in laterality vs. nonlaterality CHD mutant lines. *Bottom*: Distribution of ciliome CHD genes affecting motile vs. primary cilia among laterality vs. nonlaterality lines (From Li et al. [11])

from our screen, atrioventricular septal defects were commonly observed, and this was associated with a selective loss of cilia only in the atrioventricular cushions, while the outflow cushions remain unaffected (Fig. 8.5o–r). The overall marked enrichment observed for cilia mutations in the context of a gene agnostic screen would point to the cilia as playing a central role in the pathogenesis of congenital heart disease, a role that is subserved by both motile and primary cilia and goes beyond the role of cilia in left-right patterning.

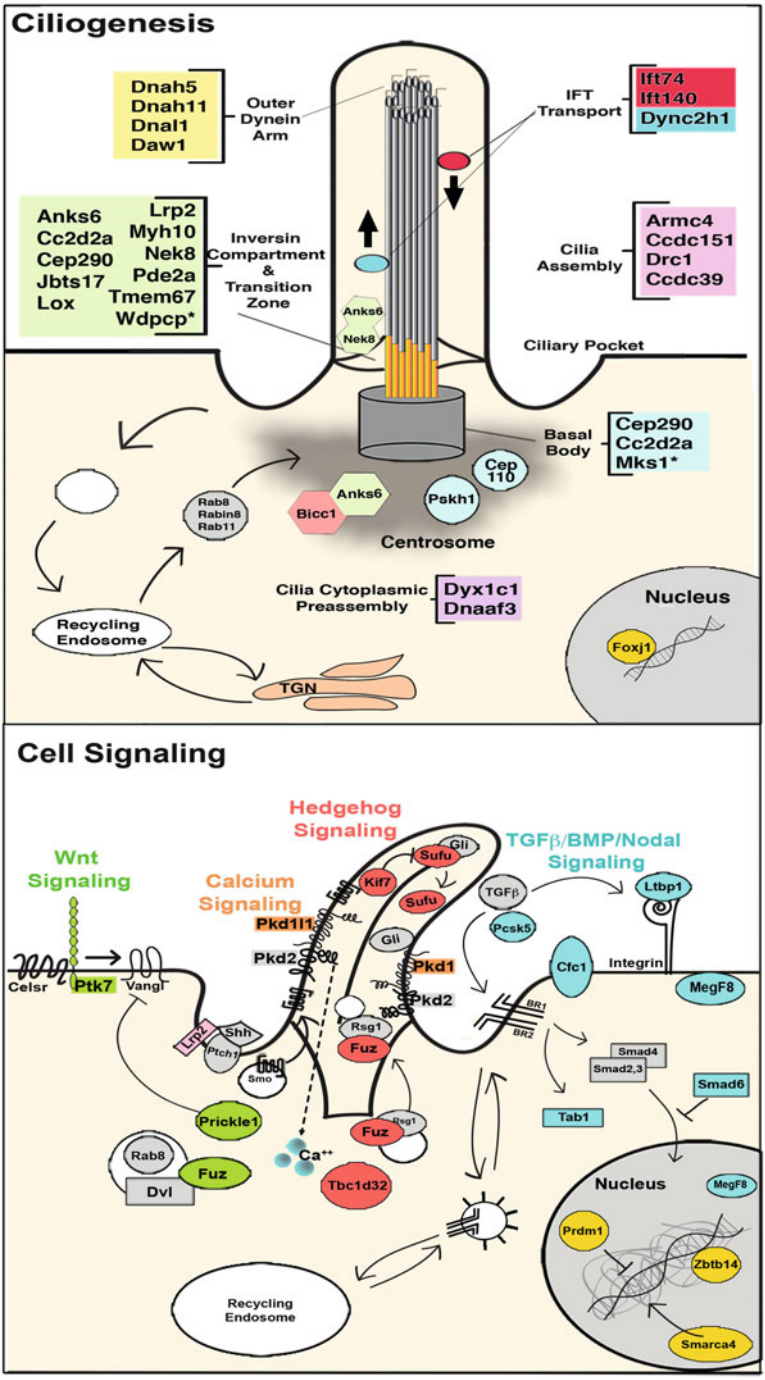

Fig. 8.5 Congenital heart disease genes recovered from mouse mutagenesis screen. Diagrams illustrate biological context of CHD gene function (*color-highlighting* indicates CHD genes recovered; *asterisk* denotes CHD genes recovered from previous screen) (From Li et al. [11])

8.1.7 Ciliary Dysfunction in Congenital Heart Disease Patients Without Heterotaxy

The finding from our mouse studies that cilia defects play a central role in the pathogenesis of CHD would suggest the clinical impact of ciliary dysfunction in congenital heart disease may be broader and have relevance beyond heterotaxy. To examine this question, we conducted a large clinical study of over 200 patients with a broad spectrum of congenital heart disease mostly without heterotaxy to determine the prevalence of ciliary dysfunction [17]. As in our previous study of heterotaxy patients, we assessed for respiratory ciliary dysfunction using videomicroscopy of the nasal epithelia and measured nNO.

This study demonstrated a very high prevalence of ciliary dysfunction, in both the heterotaxy and nonheterotaxy congenital heart disease patients [17]. Moreover, patients with airway ciliary dysfunction had significantly more respiratory symptoms and disease and this did not correlate with heterotaxy status (Table 8.1) [17]. The respiratory symptoms were largely localized to the lower airway and were also significantly associated with PCD symptoms such as chronic otitis media, chronic sinusitis, chronic wet cough, neonatal respiratory distress, pneumonia, and bronchiectasis. Together these findings suggest patients with congenital heart disease of a wide spectrum with or without heterotaxy may have high risk for respiratory ciliary dysfunction. These findings are in agreement with the mouse studies showing a central role for cilia in the pathogenesis of congenital heart disease.

8.1.8 Future Directions and Clinical Implications

We identified a central role for cilia in the pathogenesis of congenital heart disease. This finding uncovered by our mouse mutagenesis screen was unexpected and shows the power of a non-gene-biased phenotype-driven genetic screen to uncover new insights into mechanisms of disease pathogenesis. The important role of cilia in congenital heart disease is supported by the human clinical studies, which also showed a high prevalence of ciliary dysfunction in congenital heart disease patients. Our mouse screen identified primary and motile cilia both playing essential roles in congenital heart disease. The high prevalence of laterality defects among congenital heart disease mutants is reminiscent of the clinicalx observation of a high prevalence of heterotaxy among human fetuses with congenital heart disease. This suggests that observations from our mouse fetal ultrasound screen may provide a window into the unborn human fetal population.

Our finding that congenital heart disease patients with ciliary dysfunction have more respiratory symptoms and disease has important clinical implications. Patients with complex congenital heart disease typically must endure multiple high-risk cardiac surgeries for palliation of their structural heart defects. Not infrequently, respiratory complications with high morbidity are observed postoperatively that can negatively impact outcome. Such respiratory problems are typically

Table 8.1 Multivariate analysis and respiratory symptoms[a]

	All symptoms		PCD symptoms		Upper symptoms		Lower symptoms	
Covariates	exp(b)	*P-value*	exp(b)	*P-value*	exp(b)	*P-value*	exp(b)	*P-value*
HTX vs. non-HTX	1.103	0.51	1.067	0.75	1.223	0.31	0.973	0.90
Abnormal vs. normal CM	1.426	**0.006**	1.423	**0.043**	1.178	0.4	1.786	**0.003**
Low vs. normal nNO	2.030	**0.002**	2.291	**0.005**	1.520	0.22	2.643	**0.001**

From Garrod et al. [17]

Definition of abbreviations: CM ciliary motion, *HTX* heterotaxy, *nNO* nasal nitric oxide, *PCD* primary ciliary dyskinesia

Significant *P* values are bolded

[a]In each log-linear regression model, the regression coefficient exp (β) represents one unit increase in the covariate x as a multiplicative effect on the mean of the outcome. When exp (β) >1, the mean of the outcome increases as x increases; if exp (β) <1, the mean of the outcome decreases as x increases

attributed to the heart disease, and the possibility of intrinsic airway clearance defects due to ciliary dysfunction is never considered and hence not tested nor treated. The observations from the human and mouse studies combined would strongly suggest congenital heart disease patients should be presurgically screened for respiratory ciliary dysfunction, and those with ciliary dysfunction should be provided perioperative pulmonary therapy to enhance airway clearance function. Instituting such change in the standard of care may have significant benefit in improving outcome, especially cumulatively through the multiple rounds of surgery that patients with critical congenital heart disease must endure.

Acknowledgments This work was supported by NIH grant HL-U01098180 and funding from the Pennsylvania Department of Health.

Open Access This chapter is distributed under the terms of the Creative Commons Attribution-Noncommercial 2.5 License (http://creativecommons.org/licenses/by-nc/2.5/) which permits any noncommercial use, distribution, and reproduction in any medium, provided the original author(s) and source are credited.

The images or other third party material in this chapter are included in the work's Creative Commons license, unless indicated otherwise in the credit line; if such material is not included in the work's Creative Commons license and the respective action is not permitted by statutory regulation, users will need to obtain permission from the license holder to duplicate, adapt or reproduce the material.

References

1. Sutherland MJ, Ware SM. Disorders of left–right asymmetry: heterotaxy and situs inversus. Am J Med Genet C: Semin Med Genet. 2009;151C(4):307–17.
2. Lin AE, Ticho BS, Houde K, Westgate NM, Holmes LB. Heterotaxy: associated conditions and hospital-based prevalence in newborns. Genet Med. 2000;2(3):157–72.
3. Kennedy MP, et al. Congenital heart disease and other heterotaxic defects in a large cohort of patients with primary ciliary dyskinesia. Circulation. 2007;115(22):2814–21.
4. Shapiro AJ, et al. Laterality defects other than situs inversus totalis in primary ciliary dyskinesia: insights into situs ambiguus and heterotaxy. Chest. 2014;146(5):1176–86.
5. Ostrowski LE, Dutcher SK, Lo CW. Cilia and models for studying structure and function. Proc Am Thorac Soc. 2011;8(5):423–9.
6. Li Y, et al. Respiratory motile cilia dysfunction in a patient with cranioectodermal dysplasia. Am J Med Genet A. 2015. doi:10.1002/ajmg.a.37133.
7. Nakleh N, et al. High prevalence of respiratory ciliary dysfunction in congenital heart disease patients with heterotaxy. Circulation. 2012;125:2232–42.
8. Tan SY, et al. Heterotaxy and complex structural heart defects in a mutant mouse model of primary ciliary dyskinesia. J Clin Invest. 2007;117(12):3742–52.
9. Harden B, et al. Increased postoperative respiratory complications in heterotaxy congenital heart disease patients with respiratory ciliary dysfunction. J Thorac Cardiovasc Surg. 2014;147 (4):1291–1298.e2.
10. Liu X, et al. Interrogating congenital heart defects with noninvasive fetal echocardiography in a mouse forward genetic screen. Circ Cardiovasc Imag. 2014;7(1):31–42.
11. Li Y, et al. Global genetic analysis in mice unveils central role for cilia in congenital heart disease. Nature. 2015. doi:10.1038/nature14269(2015).

12. Atkinson DE, Drant S. Diagnosis of heterotaxy syndrome by fetal echocardiography. Am J Cardiol. 1998;82(9):1147–9. A10.
13. Berg C, et al. Prenatal diagnosis of cardiosplenic syndromes: a 10-year experience. Ultrasound Obstet Gynecol. 2013;22(5):451–9.
14. Taketazu M, Lougheed J, Yoo SJ, Lim JS, Hornberger LK. Spectrum of cardiovascular disease, accuracy of diagnosis, and outcome in fetal heterotaxy syndrome. Am J Cardiol. 2006;97(5):720–4.
15. Pepes S, Zidere V, Allan LD. Prenatal diagnosis of left atrial isomerism. Heart. 2009;95 (24):1974–7.
16. Friedberg MK, et al. Prenatal detection of congenital heart disease. J Pediatr. 2009;155 (1):26–31.
17. Garrod AS, et al. Airway ciliary dysfunction and sinopulmonary symptoms in patients with congenital heart disease. Ann Am Thorac Soc. 2014;11(9):1426–32.