

Summary and Conclusions

Post mortem imaging could supplement or even replace autopsies. Provided that the imaging methods used are reliable, this could improve information on the cause of death and feedback to health and medical services. In Sweden the number of clinical autopsies has been declining for decades. Post mortem imaging is easier to carry out and this raises the question of whether these techniques should be applied more frequently than at present.

In this report, post mortem imaging is evaluated not only as an alternative to clinical autopsy, but also as a complement to clinical and medico-legal autopsy (Figure 1).

Conclusions

- ▶ Based on currently available evidence, it is not possible to determine the reliability of post mortem imaging as a complement or alternative to autopsy. Individual studies suggest that post mortem imaging could be useful for determining organ weights, for example, but further studies are required for confirmation.
- ▶ Further studies are required to determine the benefits of post mortem imaging in clinical and forensic autopsies. These studies should meet the following requirements: greater conformity of study design, improved study quality and larger, preferably multicenter studies.
- ▶ The greatest need for research in this field pertains to conditions in which there is a risk that autopsy could fail to detect important findings, and where it is considered difficult to extrapolate knowledge and experience from studies on living individuals.

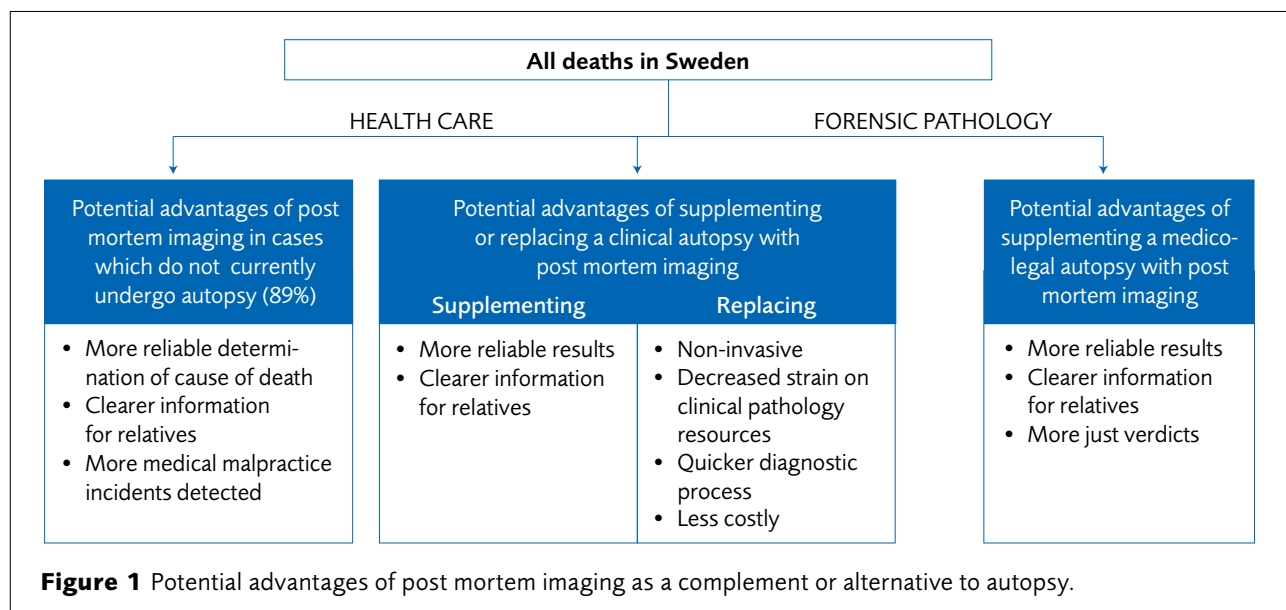


Figure 1 Potential advantages of post mortem imaging as a complement or alternative to autopsy.

Current practice

Post mortem imaging in clinical autopsies is unusual in Sweden and is limited to certain hospitals, primarily in cases of perinatal and neonatal deaths.

Post mortem imaging has been used for more than 100 years in forensic pathology as a complement to autopsy, primarily in trauma cases, to locate gas, fractures, and bullets. Post mortem imaging can also be used to reconstruct and interpret a sequence of events and to illustrate this in a legal process. Post mortem imaging is currently used in about 2% of all medico-legal autopsies in Sweden.

Ethical aspects

Post mortem imaging is a non-invasive procedure, and thus unlikely to be objectionable to relatives of the deceased. The reliability of post mortem imaging has not been scientifically confirmed, which is important in many contexts. Should post mortem imaging methods prove to be sufficiently reliable, this could improve information on the cause of death for relatives, feedback to the health and medical services and legal certainty. Low reliability could have the opposite effect. Hence, it is important for decision makers to be aware that the reliability of the methods has yet to be established.

Financial aspects

Whether post mortem imaging can replace or complement autopsy is at present undetermined, hence no meaningful cost-benefit analysis can be undertaken.

In Sweden, the cost in 2014 of a post mortem CT scan ranged from SEK 3700 to 9400. The cost of a medico-legal autopsy was estimated at SEK 26 900, while the cost of a clinical autopsy ranged from SEK 5100 to 12 500.

Project group

Experts

Anders Eriksson, Professor of Forensic Medicine, Umeå University

Anders Persson, Professor of Radiology, Center for Medical Image Science and Visualization, Linköping University

Torfinn Gustafsson, medical student, Umeå University

Legal expert: Manólis Nymark, Deputy General Counsel, Swedish National Board of Forensic Medicine

Ethics expert: Lars Sandman, Professor of Ethics, University of Borås

SBU

Monica Hultcrantz (Project Director)

Malin Höistad (Project Director)

Stella Jacobson (Assistant Project Director)

Ingegerd Mejäre (Assistant Project Director)

Thomas Davidson (Health Economist)

Anders Norlund (Health Economist)

Anna Attergren Granath (Project Administrator)

Hanna Olofsson (Information Specialist)

Scientific reviewers

Niels Lynnerup, Professor of Forensic Anthropology, University of Copenhagen

Jytte Banner, Professor of Forensic Pathology, University of Copenhagen

Christer Sundström, Professor Emeritus of Clinical Pathology, Uppsala University Hospital, Sweden

Carl Winskog, Associate Professor, University of Adelaide

SBU Alert report no 2015-01

www.sbu.se/en • registrator@sbu.se