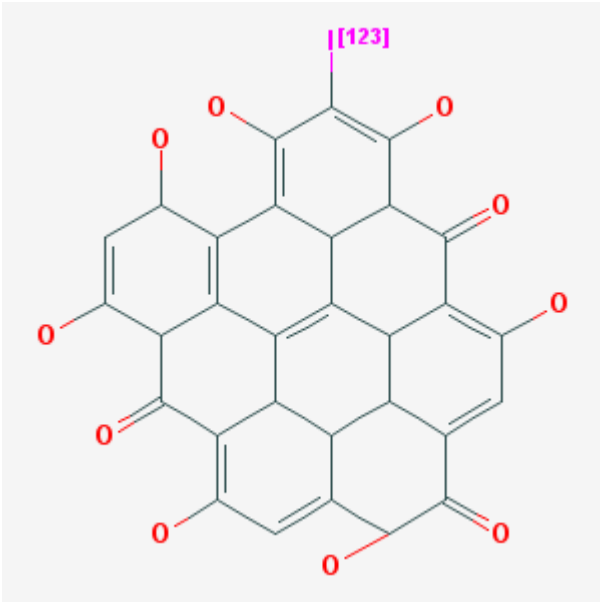


Mono-[¹²³I]iodohypericine monocarboxylic acid

[¹²³I]MIHA

Arvind Chopra, PhD¹

Created: February 21, 2008; Updated: June 2, 2008.

Chemical name:	Mono-[¹²³ I]iodohypericine monocarboxylic acid	
Abbreviated name:	[¹²³ I]MIHA	
Synonym:	[¹²³ I]16-iodo-3-methyl-hexadecanoic acid	
Agent Category:	Compound	
Target:	Necrotic tissue	
Target Category:	Uptake	
Method of detection:	Single-photon emission computed tomography (SPECT) or gamma planar imaging	
Source of Signal/ Contrast:	¹²³ I	
Activation:	No	
Studies:	<ul style="list-style-type: none"> <i>In vitro</i> Rodents 	

¹ National Center for Biotechnology Information, NLM, NIH, Bethesda, MD 20894; Email: micad@ncbi.nlm.nih.gov.

Background

[PubMed]

The myocardial perfusion imaging technique is often used to diagnose acute myocardial infarction (AMI) with either positron emission tomography (PET) or single-photon emission computed tomography (SPECT) with the use of radiopharmaceuticals, but all these agents have limitations as described in detail by Cuocolo et al. (1). It is well known that a rapid diagnosis of AMI is important to develop a suitable treatment and increase the chances of a favorable outcome. The use of scintigraphic agents such as pyrophosphate labeled with radioactive technetium (^{99m}Tc), which targets the calcium phosphate deposit in the myocardial tissue or the F(ab) fragment of an anti-myosin antibody (labeled with radioactive indium), and ^{99m}Tc -labeled glucarate has been attempted in the diagnosis of AMI, but the diagnostic performance of these agents is not entirely satisfactory (2). The pyrophosphate shows a low affinity and specificity for the necrotic myocardium in AMI patients, and the anti-myosin antibody is no longer available commercially (2). Although [^{99m}Tc]glucarate appears to be a promising agent for the detection and quantification of AMI, this agent is rapidly washed out from the infarcted myocardium, which means that a meaningful scan can be obtained only for a short time (<9 h) after the infarct has occurred because [^{99m}Tc]glucarate targets positively charged histones that disintegrate rapidly in the necrotic tissue (2). Another promising radiochemical used for the detection and diagnosis of AMI is [^{123}I]- β -methyl iodophenyl-pentadecanoic acid (also known as mono iodohypericin carboxylic acid or MIHA), a fatty acid derivative labeled with radioactive iodine (^{123}I); this agent has been widely used in Japan and Europe for SPECT imaging of the heart and is undergoing clinical evaluation in the United States (3-5).

It has been shown that photosensitizer porphyrin derivatives specifically target the necrotic tissue found in neoplastic tumors and can be used in photodynamic therapy of cancer (6). Because porphyrins bind primarily to necrotic tissue, these compounds could be used as magnetic resonance imaging contrast agents to visualize AMI under preclinical conditions (7, 8). Bearing this in mind, investigators have evaluated the use of hypericin, a polycyclic polyaromatic quinone found in the St. John's wort plant (*Hypericum perforatum*) that has a chemical structure similar to some porphyrin derivatives, for the detection and imaging of necrotic tissue, including AMI-caused necrotic tissue (9-12). To achieve this, hypericin was derivatized with radioactive iodine (^{123}I) to mono- [^{123}I]iodohypericin ([^{123}I]MIH) and used in the imaging studies with SPECT (9-12). In these studies, the investigators observed that [^{123}I]MIH had a slow plasma clearance under *in vivo* conditions, probably because it has a lipophilic character, and AMI was not visualized for at least 2 h after treatment with the radiochemical (13). The investigators hypothesized that a hypericine derivative with low lipophilicity would be cleared faster from circulation and allow early visualization of necrotic tissue. The investigators derivatized [^{123}I]MIH to a monocarboxylic acid ([^{123}I]MIHA), which has a lower lipophilicity than MIH, and evaluated this new agent for the detection of necrotic tissue in rats with ethanol-induced liver necrosis (13).

Synthesis

[PubMed]

The synthesis of $[^{123}\text{I}]\text{MIHA}$ was described in detail by Fonge et al. (13). Briefly, emodin, a precursor of hypericin, was acetylated to produce triacetyl-emodin, which was oxidized to obtain triacetyl-emodic acid. The triacetyl-emodic acid was mixed with emodin in presence of hydroquinone (serving as a free radical scavenger) to yield protohypericin monocarboxylic acid. The protohypericin derivative was photocyclized by irradiation with a 400-W halogen lamp for 30 min to obtain hypericin monocarboxylic acid, which was used as a precursor to synthesize MIHA by an electrophilic substitution reaction using sodium iodide (NaI) with peracetic acid as the oxidizing agent.

To produce $[^{123}\text{I}]\text{MIHA}$, protohypericin monocarboxylic acid was radioiodinated by the successive addition of ethanol, phosphoric acid, peracetic acid, and $\text{Na}[^{123}\text{I}]$. The mixture was incubated at room temperature for 30 min and photocyclized for 30 min with a 400-W halogen lamp. $[^{123}\text{I}]\text{MIHA}$ was purified with reverse-phase high-performance liquid chromatography coupled with a radiometric detector on an XTerra C_{18} column. The radiochemical yield was >75% relative to the initial ^{123}I activity. The specific activity of the radiochemical was 950 GBq/ μmol (25.67 Ci/ μmol). The radiochemical purity and stability of $[^{123}\text{I}]\text{MIHA}$ was not provided (13).

In Vitro Studies: Testing in Cells and Tissues

[PubMed]

An isolated, isovolumically beating rabbit heart under ischemic conditions was used to study the myocardial kinetics of $[^{123}\text{I}]\text{MIHA}$ (14). The investigators reported that the early retention fraction of MIHA under these conditions was dependent on the coronary flow, and the early retention fraction was higher under ischemic conditions than that of the normal controls (0.24 ± 0.10 and 0.14 ± 0.04 , respectively, $P = 0.004$).

Animal Studies

Rodents

[PubMed]

Normal NMRI mice were used in a preliminary investigation of $[^{123}\text{I}]\text{MIHA}$ biodistribution after a tail vein injection of the radiochemical (13). For comparison, $[^{123}\text{I}]\text{MIH}$ was injected into another group of mice through the same route. The animals from both groups were euthanized at various time points between 30 min and 24 h after injection ($n = 4$ mice per time point). Organs were removed from the animals and weighed, and the incorporated radioactivity was counted. Although both radiochemicals had a high incorporation in the liver, the uptake of $[^{123}\text{I}]\text{MIH}$ in this organ was higher than that of $[^{123}\text{I}]\text{MIHA}$ at all time points, indicating that the tracers were cleared

primarily through the hepatobiliary route. The blood clearance of [^{123}I]MIHA at 4 h (0.6% of injected dose/gram tissue (% ID/g)) was higher than that of [^{123}I]MIH at 4 h (28.2% ID/g). Compared to [^{123}I]MIH (<6% ID/g) the clearance of [^{123}I]MIHA (21.1% ID/g) was primarily through the kidneys at 24 h (13).

The affinity of [^{123}I]MIHA was studied in seven Wistar rats with hepatic necrosis induced by slow infusion of ethanol into the left lobe of the liver (13). The viable right lobe served as the control. The rats were injected with [^{123}I]MIHA and euthanized at 4 h ($n = 4$ animals) and 24 h ($n = 3$ animals) after injection. Both liver lobes were harvested from all animals and washed with saline, and absorbed radioactivity was counted. The tissues were subsequently frozen, and serial microtome sections were mounted on slides for autoradiography and confirmation with hematoxylin and eosin (H & E) staining. The incorporated radioactivity ratio of necrotic tissue *versus* viable tissue in terms of [^{123}I]MIHA uptake was 1.2 and 1.9 at 4 and 24 h, respectively. There was a good match between the uptake of [^{123}I]MIHA, as viewed by autoradiography, and the H & E staining of the necrotic liver sections (13). From these observations the investigators concluded that [^{123}I]MIHA was suitable for use in the detection of tissue necrosis.

Other Non-Primate Mammals

[PubMed]

No references are currently available.

Non-Human Primates

[PubMed]

No references are currently available.

Human Studies

[PubMed]

Marie et al. investigated the exercise SPECT defect (SPECT with thallium (^{201}Tl)) observed in patients with either necrotic ($n = 13$ individuals) or chronically ischemic and viable ($n = 15$ individuals) myocardium after two consecutive injections of [^{123}I]MIHA (14). Imaging was performed 15–35 min after the first injection of [^{123}I]MIHA, and the uptake was significantly higher in the ischemic areas ($74 \pm 9\%$ of the maximal left ventricle value) than in the necrotic areas ($59 \pm 7\%$; $P = 0.0001$) and lower than in the normal areas ($88 \pm 6\%$; $P = 0.0001$). Similar results were obtained after the second round of SPECT imaging (14). However, the investigators observed no change in the [^{123}I]MIHA clearance in consecutive SPECT studies with these patients.

Supplemental Information

[Disclaimers]

References

1. Cuocolo A., Acampa W., Imbriaco M., De Luca N., Iovino G.L., Salvatore M. The many ways to myocardial perfusion imaging. *Q J Nucl Med Mol Imaging*. 2005;49(1): 4–18. PubMed PMID: 15724132.
2. Flotats A., Carrio I. Non-invasive in vivo imaging of myocardial apoptosis and necrosis. *Eur J Nucl Med Mol Imaging*. 2003;30(4):615–30. PubMed PMID: 12638039.
3. Taki J., Matsunari I. Metabolic imaging using SPECT. *Eur J Nucl Med Mol Imaging*. 2007;34Suppl 1S34–48. PubMed PMID: 17479263.
4. Lin Q., Luo H., Mokler F., Beets A.L., Ambrose K.R., McPherson D.W., Kropp J., Knapp F.F. Effects of configuration on the myocardial uptake of radioiodinated 3(R)-BMIPP and 3(S)-BMIPP in rats. *J Nucl Med*. 1997;38(9):1434–41. PubMed PMID: 9293804.
5. Pastore C.J., Babich J.W., Udelson J.E. Future directions of myocardial fatty acid imaging. *J Nucl Cardiol*. 2007;14Suppl(3):S153–63. PubMed PMID: 17556184.
6. Magro C.M., Abbas A.E., Ross P. The application of photodynamic therapy in the treatment of metastatic endobronchial disease. *Lasers Surg Med*. 2006;38(5):376–83. PubMed PMID: 16671103.
7. Lee S.S., Goo H.W., Park S.B., Lim C.H., Gong G., Seo J.B., Lim T.H. MR imaging of reperfused myocardial infarction: comparison of necrosis-specific and intravascular contrast agents in a cat model. *Radiology*. 2003;226(3):739–47. PubMed PMID: 12601203.
8. Choi S.I., Choi S.H., Kim S.T., Lim K.H., Lim C.H., Gong G.Y., Kim H.Y., Weinmann H.J., Lim T.H. Irreversibly damaged myocardium at MR imaging with a necrotic tissue-specific contrast agent in a cat model. *Radiology*. 2000;215(3):863–8. PubMed PMID: 10831712.
9. Bormans G., Huyghe D., Christiaen A., Verbeke K., de Groot T., Vanbilloen H., de Witte P., Verbruggen A. Preparation, analysis and biodistribution in mice of iodine-123 labelled derivatives of hypericin. *J Label Comp Radiopharm*. 2004;47:191–198.
10. Fonge H., Van de Putte M., Huyghe D., Bormans G., Ni Y., de Witte P., Verbruggen A. Evaluation of tumor affinity of mono-[(123)I]iodohypericin and mono-[(123)I]iodoprotiohypericin in a mouse model with a RIF-1 tumor. *Contrast Media Mol Imaging*. 2007;2(3):113–9. PubMed PMID: 17546702.
11. Fonge H., Vunckx K., Wang H., Feng Y., Mortelmans L., Nuyts J., Bormans G., Verbruggen A., Ni Y. Non-invasive detection and quantification of acute myocardial infarction in rabbits using mono-[123I]iodohypericin {micro}SPECT. *Eur Heart J*. 2008;29(2):260–9. PubMed PMID: 18156139.
12. Ni Y., Huyghe D., Verbeke K., de Witte P.A., Nuyts J., Mortelmans L., Chen F., Marchal G., Verbruggen A.M., Bormans G.M. First preclinical evaluation of mono-[123I]iodohypericin as a necrosis-avid tracer agent. *Eur J Nucl Med Mol Imaging*. 2006;33(5):595–601. PubMed PMID: 16450141.

13. Fonge H., Jin L., Wang H., Ni Y., Bormans G., Verbruggen A. Synthesis and preliminary evaluation of mono-[123I]iodohypericin monocarboxylic acid as a necrosis avid imaging agent. *Bioorg Med Chem Lett.* 2007;17(14):4001–5. PubMed PMID: 17507220.
14. Marie P.Y., Menu P., Angioi M., Mertes P.M., Ayalew A., Hassan N., Olivier P., Fagret D., Karcher G., Danchin N., Pasqualini R., Bertrand A. The kinetics of beta-methyl-substituted labelled fatty acids in ischaemic myocardium: an analysis in man and with a blood-perfused isolated heart model. *Eur J Nucl Med.* 1999;26(5):474–82. PubMed PMID: 10382090.