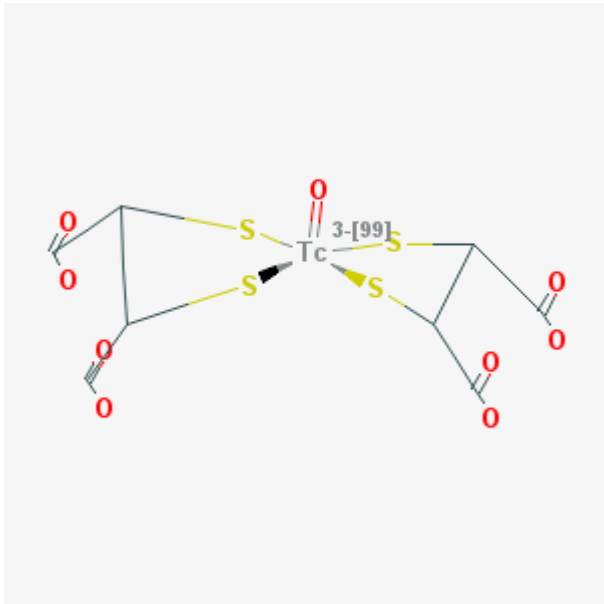


# [<sup>99m</sup>Tc]-Pentavalent dimercaptosuccinic acid

[<sup>99m</sup>Tc]-(V)DMSA

Arvind Chopra, PhD<sup>1</sup>

Created: June 11, 2010; Updated: July 29, 2010.

<b>Chemical name:</b>	[ <sup>99m</sup> Tc]-Pentavalent dimercaptosuccinic acid	
<b>Abbreviated name:</b>	[ <sup>99m</sup> Tc]-(V)DMSA	
<b>Synonym:</b>	[ <sup>99m</sup> Tc]-DMSA	
<b>Agent Category:</b>	Compound	
<b>Target:</b>	Sodium phosphate co-transporter type III	
<b>Target Category:</b>	Transporter	
<b>Method of detection:</b>	Single-photon emission computed tomography (SPECT); gamma planar imaging	
<b>Source of signal / contrast:</b>	<sup>99m</sup> Tc	
<b>Activation:</b>	No	
<b>Studies:</b>	<ul style="list-style-type: none"><li>• <i>In vitro</i></li><li>• Rodents</li><li>• Non-primate non-rodent mammals</li><li>• Humans</li></ul>	

Click on the above structure of [<sup>99m</sup>Tc]-DMSA for additional information in [PubChem](#).

<sup>1</sup> National Center for Biotechnology Information, NLM, NIH, Bethesda, MD 20894; Email: micad@ncbi.nlm.nih.gov.

## Background

[PubMed]

Technetium-99m ( $^{99m}\text{Tc}$ )-labeled pentavalent dimercaptosuccinic acid ( $^{99m}\text{Tc}$ )-(V)DMSA has been used for renal scintigraphy (see below for references) as well as detection and postoperative evaluation of medullary carcinomas of the thyroid (MCT).  $^{99m}\text{Tc}$ -(V)DMSA has been shown to accumulate in breast tumors, head and neck cancers, osteosarcomas, and hepatocellular carcinoma (1).  $^{99m}\text{Tc}$ -(V)DMSA has been used for renal (2, 3) and metastatic tumor (4) scintigraphy in animals (2), adults (4), and children (3). The  $^{99m}\text{Tc}$  in  $^{99m}\text{Tc}$ -DMSA has been shown to exist in a trivalent (III) or a pentavalent (V) state, depending on the pH at which the radiolabeled compound was prepared.  $^{99m}\text{Tc}$ -(III)DMSA is used as a renal imaging agent, whereas  $^{99m}\text{Tc}$ -(V)DMSA is suitable for imaging cancerous tumors (5). Recently, the European Association of Nuclear Medicine revised its [guidelines](#) for the use of  $^{99m}\text{Tc}$ -(V)DMSA scintigraphy in children. Also, several [clinical trials](#) approved by the United States Food and Drug Administration to evaluate the use of unlabeled DMSA for the treatment of lead exposure, toxicity, and poisoning in children have been completed. The exact mechanism of  $^{99m}\text{Tc}$ -(V)DMSA uptake by the tumor cells is not clear, but a report suggests that cellular uptake of this radiotracer is mediated by the sodium phosphate co-transporter type III (NaPi type III) (6).

The biodistribution of  $^{99m}\text{Tc}$ -(V)DMSA has been studied in rabbits (7) and mice (8).  $^{99m}\text{Tc}$ -(V)DMSA uptake has also been used to evaluate the efficacy of chemotherapy in patients with multiple myeloma (9) or glioblastoma (10) and to investigate the correlation of breast cancer in women to breast density and expression of the calcitonin gene-related peptide (11).

### Other Sources of Information:

[Protein and mRNA](#) sequence of mouse Na-dependent phosphate transporter type II

[Chromosome location and gene information](#) for human Na-dependent phosphate transporter type II (GeneID: 6567)

## Synthesis

[PubMed]

$^{99m}\text{Tc}$ -(V)DMSA is usually synthesized with a freeze-dried kit that is commercially available from several manufacturers (click here for [product insert](#) from a manufacturer), as described by Djokic et al. (12). The kit contains DMSA, stannous chloride, ascorbic acid, sodium chloride, and inositol (as a stabilizer). Reconstitution of the kit in an acidic buffer (pH 2.0–5.0) followed by labeling with  $^{99m}\text{Tc}$ -pertechnetate was shown to yield primarily  $^{99m}\text{Tc}$ -(III)DMSA (71–80% of the total radiochemical product), but labeling closer to the physiological pH (pH 6.5–7.5) or at an alkaline pH (pH 9.0) resulted in the

formation of mainly [<sup>99m</sup>Tc]-(V)DMSA (56.0% and 98.0% at pH 6.5 and pH 9.0, respectively) (13). Hirano et al. reported a similar trend of the radiochemical yield for the trivalent and pentavalent [<sup>99m</sup>Tc]-DMSA when synthesized at acidic and alkaline pH levels, respectively (14). A method for the preparation of ultrapure [<sup>99m</sup>Tc]-(V)DMSA (radiochemical purity 100%) has also been published (15). The specific activity of the labeled compound(s) was not reported by any investigator.

Babbar et al. reported that addition of ascorbic acid to the DMSA kit developed for <sup>99m</sup>Tc labeling increased the shelf-life of the refrigerated kit (6–10°C) from 4 weeks (without ascorbic acid) to 24 weeks (13).

The existence of three isomers (*syn*-endo, anti, and *syn*-exo) of [<sup>99m</sup>Tc]-(V)DMSA has been reported by Lam et al. (16). Although [<sup>99m</sup>Tc]-(III)DMSA (R<sub>f</sub> = 0–0.1) and [<sup>99m</sup>Tc]-(V)DMSA (R<sub>f</sub> = 0.45–0.55) could be separated with thin-layer chromatography (16), separation of the three [<sup>99m</sup>Tc]-(V)DMSA isomers has not been documented. However, the three rhenium 188 (<sup>188</sup>Re)-labeled isomers of DMSA have been isolated with high-performance liquid chromatography by Blower et al. (17).

## In Vitro Studies: Testing in Cells and Tissues

[PubMed]

The *in vitro* binding of [<sup>99m</sup>Tc]-(V)DMSA to rabbit plasma using the trichloro acetic acid precipitation method was reported to be 60% compared with 97% for [<sup>99m</sup>Tc]-(III)DMSA (13). In addition, the blood clearance of [<sup>99m</sup>Tc]-(V)DMSA was observed to be faster than its trivalent analog (13). The fast blood clearance of [<sup>99m</sup>Tc]-(V)DMSA was attributed to its reduced binding to the plasma proteins.

Using three different human cancer cell lines (MCF-7 (origin: breast tumor), G152 (origin: glioblastoma multiforme), and MG-63 (origin: osteosarcoma)), it was demonstrated under *in vitro* conditions that [<sup>99m</sup>Tc]-(V)DMSA uptake in the cells was facilitated by the NaPi transporter type III (18). In another study using human U937 leukemia cells treated with VP-16, a drug that induces apoptosis in cells, increased exposure time to VP-16 reduced accumulation of both phosphate and [<sup>99m</sup>Tc]-(V)DMSA in the apoptotic cells (19).

Investigators have shown that the adsorption of [<sup>99m</sup>Tc]-(V)DMSA to commercially available calcium phosphates and hydroxyapatites (both amorphous and crystalline preparations) under *in vitro* conditions in presence of 0.1 M phosphate is reversible, is influenced by pH, and does not lead to any dissociation of the complex (16). Under the same test conditions, the adsorption of <sup>99m</sup>Tc-hydroxymethylene diphosphate to the calcium phosphates and hydroxyapatite preparations remained almost constant. The investigators concluded that the deposition of [<sup>99m</sup>Tc]-(V)DMSA was found only in certain types of bone metastases, which explained why the normal skeleton was not visible clearly in scintigrams of these cancer patients (16).

Le Jeune et al. showed there was a correlation between [ $^{99m}\text{Tc}$ ]- $(\text{V})\text{DMSA}$  uptake, the phosphatidylinositol-3-kinase (Pi3-K) and protein kinase C (PKC) activities, and the rapid cell proliferation of several malignant glioma cell lines (20). From this study, the investigators suggested that, because Pi3-K and PKC activities have a major role in progression of the glioblastoma, the degree of [ $^{99m}\text{Tc}$ ]- $(\text{V})\text{DMSA}$  uptake by the malignant glioma cells could be a good indicator of aggressiveness of the cancer.

In a study with cultured Ehrlich ascites tumor cells, Horiuchi et al. showed that the pH of the growth medium influenced the uptake of [ $^{99m}\text{Tc}$ ]- $(\text{V})\text{DMSA}$  by these cells (21). The investigators showed that the accumulation of radioactivity in these cells was  $4.75 \pm 0.38\%$  of the dose at a pH range of 8.2–7.4. At pH 7.0, accumulation of radioactivity increased to  $9.53 \pm 0.94\%$  of the dose; however, at pH 5.3 it increased to  $\sim 22\%$  of the dose.

## Animal Studies

### Rodents

[PubMed]

The biodistribution patterns of tetravalent  $^{99m}\text{Tc}$ -DMSA ([ $^{99m}\text{Tc}$ ]- $(\text{IV})\text{DMSA}$ ) and [ $^{99m}\text{Tc}$ ]- $(\text{V})\text{DMSA}$  in rats ( $n = 4$  animals/radiocompound) have been described in a technical report from 1985 (22). In this study, a higher amount of [ $^{99m}\text{Tc}$ ]- $(\text{IV})\text{DMSA}$  ( $16.4 \pm 7.4$  percent injected dose per gram tissue (%ID/g)) accumulated in the kidneys of rats compared to [ $^{99m}\text{Tc}$ ]- $(\text{V})\text{DMSA}$  ( $1.64 \pm 0.22\%$  ID/g). Also, a similar result was obtained when a 1:1 mixture of [ $^{99m}\text{Tc}$ ]- $(\text{IV})\text{DMSA}$  and [ $^{99m}\text{Tc}$ ]- $(\text{V})\text{DMSA}$  was injected into the animals, indicating that the tetravalent compound had a specificity to accumulate in the renal organs.

Babbar et al. (13) studied the biodistribution of [ $^{99m}\text{Tc}$ ]- $(\text{III})\text{DMSA}$  and [ $^{99m}\text{Tc}$ ]- $(\text{V})\text{DMSA}$  in normal mice ( $n = 5$  animals/radiochemical/time point) given an intravenous injection of the respective labeled compounds. [ $^{99m}\text{Tc}$ ]- $(\text{III})\text{DMSA}$  was reported to accumulate primarily in the liver ( $10.71 \pm 1.61$  and  $12.70 \pm 0.26\%$  ID/g at 1 h and 3 h postinjection (p.i.), respectively) and kidneys ( $18.70 \pm 0.61$  and  $16.31 \pm 0.30\%$  ID/g at 1 h and 3 h p.i., respectively), followed by bone ( $1.91 \pm 0.33$  and  $2.03 \pm 0.13\%$  ID/g at 1 h and 3 h p.i., respectively). [ $^{99m}\text{Tc}$ ]- $(\text{V})\text{DMSA}$  accumulated mainly in the bone ( $7.83 \pm 0.04$  and  $6.61 \pm 0.36\%$  ID/g at 1 h and 3 h p.i., respectively), followed by the kidneys ( $3.92 \pm 0.20$  and  $2.52 \pm 0.10\%$  ID/g at 1 h and 3 h p.i., respectively) and the liver ( $1.16 \pm 0.07$  and  $0.83 \pm 0.02\%$  ID/g at 1 h and 3 h p.i., respectively). A similar uptake profile for the two radiochemicals in mice ( $n = 5$  animals) was reported by Chauhan et al. (8). Also, using [ $^{99m}\text{Tc}$ ]- $(\text{V})\text{DMSA}$ , these investigators showed that mammary carcinoma tumors in mice could be detected by scintigraphy.

[ $^{99m}\text{Tc}$ ]- $(\text{V})\text{DMSA}$  was shown to be a better scintigraphic agent than either [ $^{99m}\text{Tc}$ ]- $(\text{III})\text{DMSA}$  or  $^{99m}\text{Tc}$ -labeled human immunoglobulin for the visualization of inflammation resulting from turpentine-induced abscesses in mice (5).

Small animal single-photon emission computed tomography (SPECT) was performed on mice using  $[^{99m}\text{Tc}]$ -DMSA (isomeric form not reported) and it the tracer was shown to have a spatial resolution of  $\sim 1$  mm, was suitable to study the renal cortex, and could be used to detect changes in the renal proximal tubule functions in mice (23).

It is well known that cancerous tumors have an acidic environment compared to normal tissues. Therefore, Horiuchi et al. investigated the correlation between  $[^{99m}\text{Tc}]$ -(V)DMSA accumulation in tumor tissue and tissue acidity in mice bearing Ehrlich ascite tumor cells (EATC) (24). Using the double-tracer autoradiography technique with  $^{14}\text{C}$ -deoxyglucose and  $[^{99m}\text{Tc}]$ -(V)DMSA, the investigators showed there was a correlation between the accumulation of  $[^{99m}\text{Tc}]$ -(V)DMSA in the EATC tumors and the glucose-induced acidification of the tissues (because aerobic glycolysis results in the formation of lactic acid).

## Other Non-Primate Mammals

[PubMed]

Watkinson et al. investigated the biodistribution of  $[^{99m}\text{Tc}]$ -(V)DMSA in rabbits with ( $n = 20$  animals) or without ( $n = 20$  animals) transplantable squamous cell carcinoma tumors (7). The investigators reported that both groups of animals showed a similar ( $P > 0.05$ ) accumulation of the tracer in the kidneys, bone, blood, and the bladder. However, contrary to results obtained by Yokoyama et al. (25), these investigators reported that there was no evidence of  $[^{99m}\text{Tc}]$ -(V)DMSA uptake by the tumors of rabbits in the study. The radiochemical had a bi-exponential clearance from the blood, and the major route of excretion of radioactivity was through the urine.

Ercan et al. reported that glucose acidosis increased the uptake of  $[^{99m}\text{Tc}]$ -(V)DMSA in the bacterial arthritic joints in rabbits with experimental arthritis induced by an intra-articular injection of ovalbumin (5).

## Non-Human Primates

[PubMed]

No references are currently available.

## Human Studies

[PubMed]

$[^{99m}\text{Tc}]$ -(V)DMSA scintigraphy was shown by Babbar et al. to detect MCT and metastases of breast carcinoma to the brain in patients (13). Using  $[^{99m}\text{Tc}]$ -(V)DMSA scintigraphy, the detection of MCT in a patient was also reported by Chauhan et al. (8). In another study using SPECT to compare the MCT accumulation of  $[^{99m}\text{Tc}]$ -(V)DMSA,  $^{131}\text{I}$ -labeled metaiodobenzylguanidine, or  $^{201}\text{Tl}$  chloride, only  $[^{99m}\text{Tc}]$ -(V)DMSA was

shown to detect the tumors (14), therefore confirming the earlier results obtained by Babbar et al. (13) and Chauhan et al. (8).

Basu et al. showed that [ $^{99m}\text{Tc}$ ]-( $\text{V}$ )DMSA scintigraphy could be used for the detection, diagnosis, and treatment monitoring of skeletal metastases (4). In another study with 10 patients suffering from prostate cancer metastases to the bone, it was shown that [ $^{99m}\text{Tc}$ ]-( $\text{V}$ )DMSA scans could be used to predict the biodistribution, determine tumoral and renal dosimetry, and assess the suitability of patients for treatment with [ $^{188}\text{Re}$ ]-( $\text{V}$ )DMSA, a potential therapeutic analog of the scintigraphy agent (26).

In a retrospective study of 24 women with breast cancer who had undergone preoperative scintimammography with [ $^{99m}\text{Tc}$ ]-( $\text{V}$ )DMSA, it was concluded that the uptake of this tracer was significantly higher ( $P = 0.001$ ) in cancers expressing the calcitonin gene-related peptide compared with the non-expressing peptide cancers (11). In addition, an increased uptake of [ $^{99m}\text{Tc}$ ]-( $\text{V}$ )DMSA was particularly apparent in cancers with high breast density containing mixed lesions (i.e., presence of *in situ* ductal carcinoma along with invasive ductal carcinoma).

Rajic et al. (27) evaluated the use of [ $^{99m}\text{Tc}$ ]-( $\text{V}$ )DMSA as a marker for renal function in 67 patients suffering from glomerulonephritis, and the investigators concluded that the radiotracer had limited use for precise determination of renal function in these patients. Suzuki et al. (28) used [ $^{99m}\text{Tc}$ ]-( $\text{V}$ )DMSA to evaluate the renal function of four children suffering from idiopathic tubular proteinuria (also known as [Dent disease](#)) and observed that a low amount of the tracer was retained in the kidney because it was rapidly cleared from the organ into the bladder. On the basis of these results, the investigators suggested that renal scintigraphy with [ $^{99m}\text{Tc}$ ]-( $\text{V}$ )DMSA could be a useful method to evaluate the renal function of these patients. Similar results were reported by Lee et al. in a recent study with 13 patients (children and adults) having either [Dent disease](#) ( $n = 7$  patients) or [Lowe syndrome](#) ( $n = 6$  patients) (29).

Stathaki et al. evaluated the use of [ $^{99m}\text{Tc}$ ]-( $\text{V}$ )DMSA and compared the results to scintigraphic results with [ $^{99m}\text{Tc}$ ]-labeled hexamethylpropylene amine oxime white blood cell ([ $^{99m}\text{Tc}$ ]-HMPAO WBC) for the detection and assessment of [inflammatory bowel disease](#) (IBD) in 10 patients (30). From this study, the investigators concluded that [ $^{99m}\text{Tc}$ ]-( $\text{V}$ )DMSA scintigraphy could be a non-invasive alternative to the use of [ $^{99m}\text{Tc}$ ]-HMPAO WBC for the evaluation of IBD in the patients. However, [ $^{99m}\text{Tc}$ ]-( $\text{V}$ )DMSA scintigraphy was slightly inferior to [ $^{99m}\text{Tc}$ ]-HMPAO WBC scintigraphy in determining localization of the disease.

Koutsikos et al. (9) evaluated the use of combined scintigraphy with  $^{99m}\text{Tc}$ -labeled sestamibi ([ $^{99m}\text{Tc}$ ]-sestamibi) and [ $^{99m}\text{Tc}$ ]-( $\text{V}$ )DMSA to monitor the chemotherapeutic response in 20 patients with [multiple myeloma](#) (11 patients evaluated with [ $^{99m}\text{Tc}$ ]-sestamibi (group A), and 9 patients in remission with [ $^{99m}\text{Tc}$ ]-( $\text{V}$ )DMSA (group B)). The number of non-active lesions (NAL) and the total number of uptake-positive lesions (TPL) were determined in the two patient groups as described elsewhere (9), and the NAL/TPL ratios, which represent effectively treated lesions, were calculated. The

NAL/TPL ratios were 16:58 for group A and 22:27 for group B, indicating that 27.6% and 81.5% of the lesions were effectively treated in groups A and B, respectively. From this study, the investigators concluded that the NAL/TPL ratios with the two scintigraphy agents could be used to evaluate the chemotherapeutic response in multiple myeloma patients even if a tumor baseline was not available for the patients.

Tsiouris et al. (10) performed a clinical study with a patient suffering from recurrent [glioblastoma multiforme](#) to evaluate the use of [<sup>99m</sup>Tc]-(V)DMSA uptake by the tumor cells as a marker of the proliferative potential of the cancerous tumor. The tumor had been surgically removed from the patient, followed by adjuvant radio- and chemotherapy, but magnetic resonance imaging confirmed recurrence of the cancer a few months later. A second round of chemotherapy did not improve the patient's condition, and [<sup>99m</sup>Tc]-(V)DMSA scintigraphy revealed there was almost no change in proliferation of the tumor after chemotherapy. On the basis of this study, the investigators suggested that scintigraphy with this radiochemical could be used as a non-invasive tumor cell proliferation marker and that this technique may be useful to monitor cancer therapy response(s), predict patient prognosis, and inform patient management.

## Supplemental Information

[Disclaimers]

No supplemental information is currently available.

### References

1. Bozkurt M.F., Ugur O., Banti E., Grassetto G., Rubello D. *Functional nuclear medicine imaging of medullary thyroid cancer*. Nucl Med Commun. 2008;29(11):934–42. PubMed PMID: 18836370.
2. Cabuk M., Gurel A., Sen F., Demircan N. *Renoprotective effect of erdosteine in rats against gentamicin nephrotoxicity: a comparison of <sup>99m</sup>Tc-DMSA uptake with biochemical studies*. Mol Cell Biochem. 2008;308(1-2):35–42. PubMed PMID: 17899318.
3. Yiee, J.H., M. Disandro, M.H. Wang, A. Hittelman, and L.S. Baskin, *Does Severity of Renal Scarring on DMSA Scan Predict Abnormalities in Creatinine Clearance?* Urology.
4. Basu S., Nair N., Awasare S., Tiwari B.P., Asopa R., Nair C. *<sup>99m</sup>Tc(m)(V)DMSA scintigraphy in skeletal metastases and superscans arising from various malignancies: diagnosis, treatment monitoring and therapeutic implications*. Br J Radiol. 2004;77(916):347–61. PubMed PMID: 15107330.
5. Ercan M.T., Gulaldi N.C., Unsal I.S., Aydin M., Peksoy I., Hascelik Z. *Evaluation of Tc-<sup>99m</sup>(V) DMSA for imaging inflammatory lesions: an experimental study*. Ann Nucl Med. 1996;10(4):419–23. PubMed PMID: 9006727.
6. Papantoniou V., Tsiouris S., Mainta E., Valotassiou V., Souvatzoglou M., Sotiropoulou M., Nakopoulou L., Lazaris D., Louvrou A., Melissinou M., Tzannetaki A., Pirmettis I., Koutsikos J., Zerva C. *Imaging in situ breast carcinoma (with or without an invasive*

- component) with technetium-99m pentavalent dimercaptosuccinic acid and technetium-99m 2-methoxy isobutyl isonitrile scintimammography. *Breast Cancer Res.* 2005;7(1):R33–45. PubMed PMID: 15642168.
7. Watkinson J.C., Allen S.J., Laws D.E., Lazarus C.R., Maisey M.N., Clarke S.E. *The pharmacokinetics and biodistribution of technetium-99m(V)dimercaptosuccinic acid in an animal tumor model.* *J Nucl Med.* 1991;32(6):1235–8. PubMed PMID: 1646304.
  8. Chauhan U.P., Babbar A., Kashyap R., Prakash R. *Evaluation of a DMSA kit for instant preparation of 99mTc(V)-DMSA for tumour and metastasis scintigraphy.* *Int J Rad Appl Instrum B.* 1992;19(8):825–30. PubMed PMID: 1330991.
  9. Koutsikos J., Athanasoulis T., Anagnostopoulos A., Velidaki A., Passadi M., Dimopoulos M.A., Zerva C. *Combined use of 99mTc-sestamibi and 99mTc-V-DMSA in the assessment of chemotherapy effectiveness in patients with multiple myeloma.* *J Nucl Med.* 2005;46(6):978–82. PubMed PMID: 15937309.
  10. Tsiouris S., Pirmettis I., Chatzipanagiotou T., Ptohis N., Papantoniou V. *Pentavalent technetium-99m dimercaptosuccinic acid [99m Tc-(V)DMSA] brain scintitomography-- a plausible non-invasive depicter of glioblastoma proliferation and therapy response.* *J Neurooncol.* 2007;85(3):291–5. PubMed PMID: 17554495.
  11. Papantoniou, V., E. Sotiropoulou, P. Valsamaki, A. Tsaroucha, M. Sotiropoulou, N. Ptohis, A. Stipsanelli, K. Dimitrakakis, S. Marinopoulos, S. Tsiouris, and A. Antsaklis, *Breast density, scintimammographic (99m)Tc(V)DMSA uptake, and calcitonin gene related peptide (CGRP) expression in mixed invasive ductal associated with extensive in situ ductal carcinoma (IDC + DCIS) and pure invasive ductal carcinoma (IDC): correlation with estrogen receptor (ER) status, proliferation index Ki-67, and histological grade.* *Breast Cancer.*
  12. Djokic D., Jankovic D., Nikolic N. *Preparation and in vivo evaluation of 90Y-meso-dimercaptosuccinic acid (90Y-DMSA) for possible therapeutic use: comparison with 99mTc-DMSA.* *Cancer Biother Radiopharm.* 2009;24(1):129–36. PubMed PMID: 19243255.
  13. Babbar A., Kashyap R., Chauhan U.P. *A convenient method for the preparation of 99mTc-labelled pentavalent DMSA and its evaluation as a tumour imaging agent.* *J Nucl Biol Med.* 1991;35(2):100–4. PubMed PMID: 1657203.
  14. Hirano T., Tomiyoshi K., Zhang Y.J., Ishida T., Inoue T., Endo K. *Preparation and clinical evaluation of technetium-99m dimercaptosuccinic acid for tumour scintigraphy.* *Eur J Nucl Med.* 1994;21(1):82–5. PubMed PMID: 8088289.
  15. Kumar V. *Evaluation of stannous oxidation in the preparation of ultrahigh-purity 99m Tc(V)-DMSA.* *Nucl Med Commun.* 2001;22(11):1261–6. PubMed PMID: 11606894.
  16. Lam A.S., Puncher M.R., Blower P.J. *In vitro and in vivo studies with pentavalent technetium-99m dimercaptosuccinic acid.* *Eur J Nucl Med.* 1996;23(12):1575–82. PubMed PMID: 8929310.
  17. Blower P.J., Lam A.S., O'Doherty M.J., Kettle A.G., Coakley A.J., Knapp F.F. Jr. *Pentavalent rhenium-188 dimercaptosuccinic acid for targeted radiotherapy: synthesis and preliminary animal and human studies.* *Eur J Nucl Med.* 1998;25(6):613–21. PubMed PMID: 9618576.



18. Denoyer D., Perek N., Le Jeune N., Frere D., Dubois F. *Evidence that <sup>99m</sup>Tc-(V)-DMSA uptake is mediated by NaPi cotransporter type III in tumour cell lines.* Eur J Nucl Med Mol Imaging. 2004;31(1):77–84. PubMed PMID: 14557898.
19. Denoyer D., Perek N., Jeune N.L., Frere D., Sabido O., Clotagatide A., Dubois F. *In vitro and in vivo evaluation of the influence of type III NaPi co-transporter activity during apoptosis on <sup>99m</sup>Tc-(V)DMSA uptake in the human leukaemic cell line U937.* Eur J Nucl Med Mol Imaging. 2004;31(10):1421–7. PubMed PMID: 15205924.
20. Le Jeune N., Perek N., Dubois F. *Influence of Pi3-K and PKC activity on <sup>99m</sup>Tc-(V)-DMSA uptake: correlation with tumour aggressiveness in an in vitro malignant glioblastoma cell line model.* Eur J Nucl Med Mol Imaging. 2006;33(10):1206–13. PubMed PMID: 16763818.
21. Horiuchi K., Saji H., Yokoyama A. *pH sensitive properties of Tc(V)-DMS: analytical and in vitro cellular studies.* Nucl Med Biol. 1998;25(7):689–95. PubMed PMID: 9804051.
22. Westera G., Gadze A., Horst W. *A convenient method for the preparation of <sup>99m</sup>Tc(V)dimercaptosuccinic acid (<sup>99m</sup>Tc(V)-DMSA).* Int J Appl Radiat Isot. 1985;36(4):311–2. PubMed PMID: 2991143.
23. Jouret F., Walrand S., Parreira K.S., Courtoy P.J., Pauwels S., Devuyt O., Jamar F. *Single photon emission-computed tomography (SPECT) for functional investigation of the proximal tubule in conscious mice.* Am J Physiol Renal Physiol. 298(2):F454–60. PubMed PMID: 19955188.
24. Horiuchi K., Saji H., Yokoyama A. *Tc(V)-DMS tumor localization mechanism: a pH-sensitive Tc(V)-DMS-enhanced target/nontarget ratio by glucose-mediated acidosis.* Nucl Med Biol. 1998;25(6):549–55. PubMed PMID: 9751422.
25. Yokoyama A., Hata N., Horiuchi K., Masuda H., Saji H., Ohta H., Yamamoto K., Endo K., Torizuka K. *The design of a pentavalent <sup>99m</sup>Tc-dimercaptosuccinate complex as a tumor imaging agent.* Int J Nucl Med Biol. 1985;12(4):273–9. PubMed PMID: 3002999.
26. Blower P.J., Kettle A.G., O'Doherty M.J., Coakley A.J., Knapp F.F. Jr. *<sup>99m</sup>Tc(V)DMSA quantitatively predicts <sup>188</sup>Re(V)DMSA distribution in patients with prostate cancer metastatic to bone.* Eur J Nucl Med. 2000;27(9):1405–9. PubMed PMID: 11007525.
27. Rajic M., Bogicevic M., Antic S., Mitic B., Avramovic M., Ilic S., Vlajkovic M., Mitic-Zlatovic M., Stefanovic V. *Alteration of <sup>99m</sup>Tc-DMSA biodistribution in glomerulonephritis.* Nucl Med Rev Cent East Eur. 2002;5(1):15–9. PubMed PMID: 14600941.
28. Suzuki S., Suzuki J., Kume K., Yoshida K., Suyama H., Kawasaki Y., Nozawa R., Suzuki H., Fujiki T., Kamiyama S., Suzuki A. *Poor renal accumulation of <sup>99m</sup>Tc-DMSA in idiopathic tubular proteinuria.* Nephron. 1999;81(1):49–54. PubMed PMID: 9884419.
29. Lee B.H., Lee S.H., Choi H.J., Kang H.G., Oh S.W., Lee D.S., Ha I.S., Choi Y., Cheong H.I. *Decreased renal uptake of (<sup>99m</sup>Tc)-DMSA in patients with tubular proteinuria.* Pediatr Nephrol. 2009;24(11):2211–6. PubMed PMID: 19579036.
30. Stathaki M.I., Koutroubakis I.E., Koukouraki S.I., Karmiris K.P., Moschandreas J.A., Kouroumalis E.A., Karkavitsas N.S. *Active inflammatory bowel disease: head-to-head comparison between <sup>99m</sup>Tc-hexamethylpropylene amine oxime white blood cells and*

*99mTc(V)-dimercaptosuccinic acid scintigraphy*. Nucl Med Commun. 2008;29(1):27–32. PubMed PMID: 18049094.