



Zonisamide

Updated: January 6, 2015.

OVERVIEW

Introduction

Zonisamide is a new generation anticonvulsant that is typically used in combination with other antiepileptic medications for partial onset seizures. Zonisamide has not been associated with elevations in serum aminotransferase levels and clinically apparent drug induced liver disease has been reported with its use but is very rare.

Background

Zonisamide (zoe nis' a mide) is synthetic sulfonamide derivative related somewhat in structure to acetazolamide, but not to other anticonvulsant medications. Zonisamide appears to block the spread of seizure discharges by affecting repetitive firing of voltage-sensitive sodium and calcium channels and stabilizing neuronal membranes. Zonisamide was approved for use in epilepsy in Japan in 1989 and in the United States in 2000. Current indications include adjunctive therapy for partial seizures in adults. Zonisamide is used off-label for therapy of migraine headaches, mood disturbances and recently for weight loss. Zonisamide is available as capsules of 25, 50 and 100 mg generically and under the brand name of Zonegran. The recommended initial dose in adults with epilepsy is 100 mg in one or two doses daily, with dose escalation based upon tolerance and effect to a maximum of 200 mg twice daily. Common side effects include drowsiness, dizziness, headache, nausea, poor appetite and weight loss. Rare, but serious side effects include Stevens Johnson syndrome, toxic epidermal necrolysis, aplastic anemia and agranulocytosis.

Hepatotoxicity

Prospective studies suggest that chronic zonisamide therapy may be accompanied by mild increases in serum alkaline phosphatase levels, but it has not been linked to significant increases in serum aminotransferase levels. Clinically apparent hepatotoxicity from zonisamide is quite rare, as few case reports of hepatic injury linked to zonisamide have been published. Zonisamide is typically used in combination with other anticonvulsants and its separate role in causing liver injury is often difficult to delineate. Zonisamide has been linked to a single case report of cholestatic hepatitis associated with vanishing bile duct syndrome that ultimately resolved. More commonly, zonisamide has been linked to cases of hypersensitivity (DRESS syndrome) with rash, fever, eosinophilia, renal failure and/or mild liver test abnormalities. In most instances, the hepatic injury was cholestatic and arose 3 to 8 weeks after starting therapy.

Mechanism of Injury

The mechanism of zonisamide hepatotoxicity is unknown but is likely to be hypersensitivity. Cases of drug hypersensitivity to zonisamide have been linked to HLA-A*02:07 in Japanese subjects.

Outcome and Management

A few cases of cholestatic liver injury attributed to zonisamide has been published, with complete recovery in most patients but with persistent liver test abnormalities in at least one patient. Zonisamide has not been linked to acute liver failure or chronic liver injury. Patients who develop the anticonvulsant hypersensitivity syndrome should avoid other aromatic anticonvulsants or start them only with careful monitoring. Hypersensitivity reactions to anticonvulsants including zonisamide may benefit from corticosteroid therapy, but the efficacy of such therapy in altering the outcome of liver injury has not been proven.

Drug Class: [Anticonvulsants](#)

CASE REPORT

Case 1. Cholestatic hepatitis and bile duct injury attributed to zonisamide.

[Modified from: Vuppalanchi R, Chalasani N, Saxena R. Restoration of bile ducts in drug-induced vanishing bile duct syndrome due to zonisamide. *Am J Surg Pathol* 2006; 30: 1619-23. [PubMed Citation](#)]

An obese 35 year old man was being treated with phentermine and topiramate for weight loss. When switched from topiramate to zonisamide, he developed fatigue, dark urine and abdominal pain followed by jaundice and itching. After 3 weeks of symptoms, laboratory testing showed significant elevations in serum bilirubin, ALT and alkaline phosphatase levels (Table). There was no rash or fever. Tests for hepatitis A, B and C and for autoantibodies were negative. Abdominal ultrasound showed echogenicity of the liver compatible with hepatic steatosis, but no evidence of biliary obstruction. Endoscopic retrograde cholangiopancreatography was normal and a liver biopsy showed cholestasis with paucity of bile ducts. He persisted in having elevations in serum enzymes and underwent repeat liver biopsies 3 and 7 months after presentation, which showed ductular proliferation and improvement in cholestasis.

Key Points

Medication:	Zonisamide (dose not provided)
Pattern:	Mixed→Cholestatic (R=2.3, initially; later R <1.0)
Severity:	3+ (jaundice and hospitalization)
Latency:	3 weeks
Recovery:	Incomplete; alkaline phosphatase still elevated one year later
Other medications:	Phentermine, topiramate (stopped 3 weeks earlier)

Laboratory Values

Time After Starting	Time After Stopping	ALT (U/L)	Alk P (U/L)	Bilirubin (mg/dL)	Other
3 weeks	0	531	578	7.1	
4 weeks	1 week	240	490	9.0	
5 weeks	2 week	270	390	9.5	Biopsy #1
6 weeks	3 week	100	320	8.2	
7 weeks	4 week	80	300	7.3	

Table continued from previous page.

Time After Starting	Time After Stopping	ALT (U/L)	Alk P (U/L)	Bilirubin (mg/dL)	Other
11 weeks	8 week	90	320	5.6	
13 weeks	10 weeks	200	420	3.0	
15 weeks	12 weeks	110	510	2.0	
21 weeks	18 weeks	75	340	1.7	Biopsy #2
6 months	5 months	105	440	1.2	
1 year	11 months	120	640	0.9	Biopsy #3
Normal Values		<50	<125	<1.2	

Comment

This was a well documented example of cholestatic hepatitis presenting with histological features of bile duct injury and loss which evolved into a partially reversible bile duct vanishing syndrome. The patient had persistence of serum enzyme elevations and chronic ductular injury that was still present almost a year after onset. The injury was attributed to zonisamide, but the patient had also received topiramate that was withdrawn shortly before onset of symptoms and may have played a role in this injury. The ultimate prognosis of vanishing bile duct syndrome is variable; some patients appear to recover, others develop chronic cholestasis and cirrhosis, requiring liver transplantation.

PRODUCT INFORMATION

REPRESENTATIVE TRADE NAMES

Zonisamide – Generic, Zonegran®

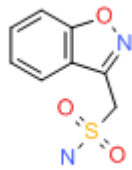
DRUG CLASS

Anticonvulsants

COMPLETE LABELING

Product labeling at DailyMed, National Library of Medicine, NIH

CHEMICAL FORMULA AND STRUCTURE

DRUG	CAS REGISTRY NUMBER	MOLECULAR FORMULA	STRUCTURE
Zonisamide	68291-97-4	C ₈ -H ₈ -N ₂ -O ₃ -S	

ANNOTATED BIBLIOGRAPHY

References updated: 06 January 2015

Zimmerman HJ. Anticonvulsants. In, Zimmerman, HJ. Hepatotoxicity: the adverse effects of drugs and other chemicals on the liver. 2nd ed. Philadelphia: Lippincott, 1999: pp. 498-516.

(Expert review of anticonvulsants and liver injury published in 1999; zonisamide is not mentioned).

Pirmohamed M, Leeder SJ. Anticonvulsant agents. In, Kaplowitz N, DeLeve LD, eds. Drug-induced liver disease. 3rd ed. Amsterdam: Elsevier, 2013: pp 423-41. *(Review of anticonvulsant induced liver injury does not specifically discuss*

zonisamide).

McNamara JO. Pharmacology of the epilepsies. In, Brunton LL, Chabner BA, Knollman BC, eds. Goodman & Gilman's the pharmacological basis of therapeutics. 12th ed. New York: McGraw-Hill, 2011, pp. 583-608. *(Textbook of pharmacology*

and therapeutics).

Natsch S, Hekster YA, Keyser A, Deckers CL, Meinardi H, Renier WO. Newer anticonvulsant drugs: role of pharmacology, drug interactions and adverse reactions in drug choice. *Drug Saf* 1997; 17: 228-40. PubMed PMID: 9352959.

(Review of pharmacology, drug interactions and adverse effects anticonvulsants introduced after 2007, including felbamate, gabapentin, lamotrigine, oxcarbazepine, topiramate and zonisamide; no mention of hepatotoxicity of zonisamide).

Knowles SR, Shapiro LE, Shear NH. Anticonvulsant hypersensitivity syndrome: incidence, prevention and management. *Drug Saf* 1999; 21: 489-501. PubMed PMID: 10612272.

(Review of anticonvulsant hypersensitivity syndrome: triad of fever, rash and internal organ injury occurring 1-8 weeks after exposure to anticonvulsant; liver being most common internal organ involved. Occurs in 1:1000-1:10,000 initial exposures to phenytoin, carbamazepine, phenobarbital or lamotrigine, unrelated to dose, perhaps predisposed by valproate; liver injury arises 1-4 weeks after onset of rash and ranges in severity from asymptomatic ALT elevations to icteric hepatitis to acute liver failure. High mortality rate with jaundice; other organs include muscle, kidney, brain, heart and lung. Role of corticosteroids uncertain; cross reactivity among the aromatic anticonvulsant agents should be assumed, but not with zonisamide).

Hamer HM, Morris HH. Hypersensitivity syndrome to antiepileptic drugs: a review including new anticonvulsants. *Clevel Clin J Med* 1999; 66: 239-45. PubMed PMID: 10199060.

(Clinical review of anticonvulsant hypersensitivity syndrome, which occurs in 1-5/10,000 of users, higher risk in African Americans and affected siblings; liver involvement common, but most cases are anicteric; other manifestations include facial edema, lymphadenopathy, bone marrow aplasia, pseudolymphoma, thyroiditis, interstitial nephritis; switching to valproate and benzodiazepines is safe, zonisamide is also an option).

Leppik IE. Zonisamide: chemistry, mechanism of action, and pharmacokinetics. *Seizure* 2004; 13 Suppl 1: S5-9. PubMed PMID: 15511691.

(Review of the pharmacology and pharmacokinetics of zonisamide).

Vuppalanchi R, Chalasani N, Saxena R. Restoration of bile ducts in drug-induced vanishing bile duct syndrome due to zonisamide. *Am J Surg Pathol* 2006; 30: 1619-23. PubMed PMID: 17122520.

(35 year old obese man developed fatigue and dark urine shortly after starting zonisamide and 3 weeks later had jaundice and itching [bilirubin 7.1 mg/dL, ALT 531 U/L, Alk P 531], biopsy showing bile duct loss, Alk P and ALT were still abnormal 10 months later; patient also had received topiramate 3 weeks before presentation: Case 1).

- LaRoche SM. A new look at the second-generation antiepileptic drugs: a decade of experience. *Neurologist* 2007; 13: 133-9. PubMed PMID: 17495757.
- (Review of second generation anticonvulsants approved since 1994 including felbamate, gabapentin, lamotrigine, topiramate, tiagabine, levetiracetam, oxcarbazepine, zonisamide and pregabalin; zonisamide associated with kidney stones, but no mention of liver toxicity).*
- Björnsson E. Hepatotoxicity associated with antiepileptic drugs. *Acta Neurol Scand* 2008; 118: 281-90. PubMed PMID: 18341684.
- (Review of all anticonvulsants; suggests that there have been no cases of hepatotoxicity associated with zonisamide).*
- Chalasanani N, Fontana RJ, Bonkovsky HL, Watkins PB, Davern T, Serrano J, Yang H, Rochon J; Drug Induced Liver Injury Network (DILIN). Causes, clinical features, and outcomes from a prospective study of drug-induced liver injury in the United States. *Gastroenterology* 2008; 135: 1924-34. PubMed PMID: 18955056.
- (Among 300 cases of drug induced liver disease in the US collected between 2004 and 2008, valproate accounted for 6, lamotrigine 5, phenytoin 5, gabapentin and topiramate 1 each; zonisamide not mentioned).*
- Reuben A, Koch DG, Lee WM; Acute Liver Failure Study Group. Drug-induced acute liver failure: results of a U.S. multicenter, prospective study. *Hepatology* 2010; 52: 2065-76. PubMed PMID: 20949552.
- (Among 1198 patients with acute liver failure enrolled in a US prospective study between 1998 and 2007, 133 were attributed to drug induced liver injury including 11 due to anticonvulsants, 8 from phenytoin, 2 valproate and 3 carbamazepine, but none were attributed to lamotrigine, levetiracetam, topiramate, or zonisamide).*
- Fujita Y, Hasegawa M, Nabeshima K, Tomita M, Murakami K, Nakai S, Yamakita T, Matsunaga K. Acute kidney injury caused by zonisamide-induced hypersensitivity syndrome. *Intern Med* 2010; 49: 409-13. PubMed PMID: 20190474.
- (29 year old man developed rash, facial edema and fever 2 months after starting zonisamide, with subsequent renal failure requiring dialysis and serum cholestatic enzyme elevations [bilirubin 0.4 mg/dL, ALT 88 U/L, Alk P 661 U/L, 26% eosinophils], with response to corticosteroid therapy and ultimate resolution).*
- Schwartz M, Muñana KR, Olby NJ. Possible drug-induced hepatopathy in a dog receiving zonisamide monotherapy for treatment of cryptogenic epilepsy. *J Vet Med Sci* 2011. [Epub ahead of print] PubMed PMID: 21720107.
- (9 year old female dog developed jaundice 3 weeks after starting zonisamide [bilirubin 4.3 mg/dL, ALT 1275 U/L, Alk P 5182 U/L], with full recovery within 4 weeks of stopping).*
- Miller ML, Center SA, Randolph JF, Lephherd ML, Cautela MA, Dewey CW. Apparent acute idiosyncratic hepatic necrosis associated with zonisamide administration in a dog. *J Vet Intern Med* 2011; 25: 1156-60. PubMed PMID: 21985145.
- (4 year old male dog developed anorexia and vomiting 10 days after starting zonisamide for epilepsy [bilirubin 2.3 mg/dL, ALT 16,328 U/L, Alk P 354 U/L], with progressive multiorgan failure and death the next day, autopsy showing massive necrosis).*
- Lu Y, Xiao Z, Yu W, Xiao F, Xiao Z, Hu Y, Chen Y, Wang X. Efficacy and safety of adjunctive zonisamide in adult patients with refractory partial-onset epilepsy: a randomized, double-blind, placebo-controlled trial. *Clin Drug Investig* 2011; 31: 221-9. PubMed PMID: 21166480.
- (Controlled trial of zonisamide in 104 patients with refractory epilepsy; liver enzyme elevations occurred in 35% of zonisamide- vs 37% of placebo-recipients and none developed clinically apparent liver injury).*
- Uhara H, Saiki M, Kawachi S, Ashida A, Oguchi S, Okuyama R. Clinical course of drug-induced hypersensitivity syndrome treated without systemic corticosteroids. *J Eur Acad Dermatol Venereol* 2012 Apr 28. [Epub ahead of print] (S PubMed PMID: 22540194.

eries of 12 patients with drug induced hypersensitivity caused by carbamazepine [6], sulfonamide [4], mexitletine [1], and zonisamide [1]; in a 62 year old woman with a brain tumor who developed fever and rash 22 days after starting zonisamide [bilirubin and Alk P not given, ALT 240 U/L], resolving without therapy).

Kaniwa N, Saito Y. Pharmacogenomics of severe cutaneous adverse reactions and drug-induced liver injury. *J Hum Genet.* 2013 May 2. [Epub ahead of print] PubMed PMID: 23635947.

(Review of genetic associations with severe skin and liver injury from drugs, focusing upon allopurinol [B*5801], abacavir and flucloxacillin [B*5701] and lapatinib [DQA1*02:01]; the association of B*1502 with carbamazepine induced SJS has not been extended to carbamazepine induced liver injury; zonisamide not discussed).

Sekula P, Dunant A, Mockenhaupt M, Naldi L, Bouwes Bavinck JN, Halevy S, Kardaun S, Sidoroff A, Liss Y, Schumacher M, Roujeau JC. Comprehensive survival analysis of a cohort of patients with Stevens-Johnson syndrome and toxic epidermal necrolysis. *J Invest Dermatol.* 2013; 133: 1197-204. PubMed PMID: 23389396.

(Analysis of mortality rates in 460 patients with SJS/TEN [67% due to drugs and 19% due to anticonvulsants] in a European observational database found that age, severity, underlying malignancy and renal or hepatic involvement correlated with poor survival; overall mortality at one year being 24% for SJS, 43% for overlap and 49% for TEN cases).

Lee T, Lee YS, Yoon SY, Kim S, Bae YJ, Kwon HS, Cho YS, Moon HB, Kim TB. Characteristics of liver injury in drug-induced systemic hypersensitivity reactions. *J Am Acad Dermatol* 2013 Apr 27. [Epub ahead of print] PubMed PMID: 23632341.

(Analysis of 136 patients with hypersensitivity reactions to drugs seen at a single referral center in Korea found liver involvement in 61 [45%], including 11 with SJS/TEN, 29 with DRESS and 17 with rash only; 20 cases were attributed to anticonvulsants, but specific agents were not discussed).

Gaitatzis A, Sander JW. The long-term safety of antiepileptic drugs. *CNS Drugs* 2013; 27: 435-55. PubMed PMID: 23673774.

(Review of the long term safety and adverse event profile of anticonvulsants mentions that valproate can cause fatty liver disease, but that most cases of clinically apparent liver injury including acute liver failure occur within the first few months of treatment with anticonvulsants such as valproate and felbamate).

Kaniwa N, Sugiyama E, Saito Y, Kurose K, Maekawa K, Hasegawa R, Furuya H, et al; Japan Pharmacogenomics Data Science Consortium. Specific HLA types are associated with antiepileptic drug-induced Stevens-Johnson syndrome and toxic epidermal necrolysis in Japanese subjects. *Pharmacogenomics* 2013; 14: 1821-31. PubMed PMID: 24236482.

(Analysis of HLA types among 12 Japanese patients with SJS/TEN due to zonisamide four 42% to have HLA-A*02:07 compared to 6.8% of controls).

Drugs for epilepsy. *Treat Guidel Med Lett* 2013; 11: 9-18. PubMed PMID: 23348233.

(Concise review of drugs of choice for epilepsy; mentions that the adverse effects of zonisamide include fatal instances of toxic epidermal necrolysis and Stevens Johnson syndrome).

Shibuya R, Tanizaki H, Nakajima S, Koyanagi I, Kataoka TR, Miyachi Y, Kabashima K. DIHS/DRESS with remarkable eosinophilic pneumonia caused by zonisamide. *Acta Derm Venereol* 2014 Apr 3. [Epub ahead of print] PubMed PMID: 24696158.

(46 year old woman developed rash, fever and cough 41 days after restarting zonisamide [bilirubin normal, ALT 133 U/L, Alk P 220 U/L, 11% eosinophils], resolving with prednisone therapy).

Baulac M, Patten A, Giorgi L. Long-term safety and efficacy of zonisamide versus carbamazepine monotherapy for treatment of partial seizures in adults with newly diagnosed epilepsy: Results of a phase III, randomized, double-blind study. *Epilepsia* 2014; 55: 1534-43. PubMed PMID: 25109239.

(Among 295 patients with partial seizures treated with either zonisamide or carbamazepine for 6 months, adverse events were similar with both drugs; no mention of ALT elevations or hepatotoxicity).