



Tedizolid

Updated: April 2, 2016.

OVERVIEW

Introduction

Tedizolid is an oxazolidinone antibiotic, similar to linezolid, which has a broad spectrum of activity against gram positive bacteria including methicillin resistant *Staphylococcus aureus* (MRSA). Tedizolid has been associated with a low rate of transient serum aminotransferase elevations during therapy, but has not been linked to instances of clinically apparent acute liver injury.

Background

Tedizolid (te diz' oh lid) is a synthetic, second generation oxazolidinone antibiotic, similar to linezolid, that has broad bactericidal activity against gram positive organisms such as enterococci and staphylococci and most streptococci. Importantly, tedizolid has potent activity against Methicillin resistant strains of *Staphylococcus aureus* (MRSA). Tedizolid acts by binding to the 50S subunit of bacterial ribosome, preventing the formation of the functional ribosomal 70S subunit and thereby blocking bacterial protein synthesis. In several randomized controlled trials, tedizolid was found to be similar in efficacy (“non-inferior”) to linezolid as therapy of acute bacterial skin and skin-structure infections. Tedizolid was approved for use in the United States in 2014 and is currently indicated for treatment of skin and skin structure infections caused by susceptible bacteria, including *Staphylococcus aureus*. Because of its activity against multidrug resistant enterococci and staphylococci, the use of tedizolid is usually reserved for severe infections where methicillin or penicillin resistance is found. Tedizolid is available in tablets of 200 mg under the name Sivextro. It is also available as a powder in single dose vials for reconstitution in solution for intravenous administration. Tedizolid is typically given as a 6 day course of 200 mg once daily, either orally or intravenously. Common minor side effects include nausea, diarrhea, abdominal upset, headache and arthralgias. Rare, but severe side effects that can occur with more prolonged therapy include serotonin syndrome, thrombocytopenia and optic and peripheral neuropathy.

Hepatotoxicity

Therapy with tedizolid has been associated with mild and transient elevations in serum aminotransferase and alkaline phosphatase levels in 1% to 4% of patients, although similar rates of elevations occur in patients with infections treated with comparable agents including linezolid. In all instances, the elevations occurred without symptoms or jaundice and resolved with discontinuation of the drug.

While tedizolid has not been linked to cases of clinically apparent liver disease with jaundice, linezolid, a similar oxazolidinone antibiotic, has been linked to cases of lactic acidosis and systemic injury. This syndrome generally arises after 1 to 8 weeks of therapy and is sometimes associated with evidence of liver injury and jaundice. Lactic acidosis is usually due to dysfunction or loss of hepatic mitochondria, with resulting microvesicular steatosis and

disturbed hepatic function (not necessarily accompanied by jaundice or even ALT or alkaline phosphatase elevations). Other serious side effects associated with mitochondrial damage include peripheral and optic neuropathy, pancreatitis, serotonin syndrome and renal injury. The mitochondrial injury is believed to be due to the inhibition of mitochondrial ribosomal function that matches the known effect of the oxazolidinones on bacterial ribosomal function. Lactic acidosis occurs after 1 to 8 weeks of treatment and can be severe, although it resolves rapidly with discontinuation. In contrast, the optic and peripheral neuropathy due to this class of antibiotics resolves more slowly and can be permanent. Lactic acidosis can be fatal, and hepatic dysfunction and jaundice have been mentioned in severe cases attributed to linezolid. This syndrome has yet to be clearly linked to tedizolid therapy.

Likelihood score: E* (unproven but suspected cause of liver injury).

Mechanism of Injury

The etiology of serum enzyme elevations during tedizolid therapy is not known and may relate more to the underlying condition rather than injury from tedizolid. Lactic acidosis and peripheral neuropathy from oxazolidinones are probably due to inhibition of mitochondrial ribosomal function and protein synthesis. Indeed, several mitochondrial DNA polymorphisms [2706A>G and 3010G>A] have been identified in patients who developed lactic acidosis while on linezolid that may have represented a genetic predisposition to this adverse event.

Outcome and Management

The serum aminotransferase and alkaline phosphatase elevations that occur during tedizolid therapy are self-limited and resolve once therapy is stopped. There are no reports of cross sensitization and hepatic injury from tedizolid in persons with hepatic injury from other antibiotics or sulfonamides. The lactic acidosis due to linezolid has been linked to injury to hepatic mitochondria and with microvesicular steatosis, but is usually rapidly reversed with withdrawal of therapy. Treatment with carnitidine, antioxidants, thiamine and prednisone has been used, but has not been shown to be effective. Use of intravenous 20% glucose infusions, which are effective in treating the lactic acidosis of acute fatty liver of pregnancy, Reye syndrome and fialuridine therapy, has not been studied. However, tedizolid has not been definitely linked to this syndrome.

Drug Class: [Antiinfective Agents](#), Miscellaneous, Oxazolidinones

Other Drugs in the Subclass, Oxazolidinones: [Linezolid](#)

PRODUCT INFORMATION

REPRESENTATIVE TRADE NAMES

Tedizolid – Sivextro®

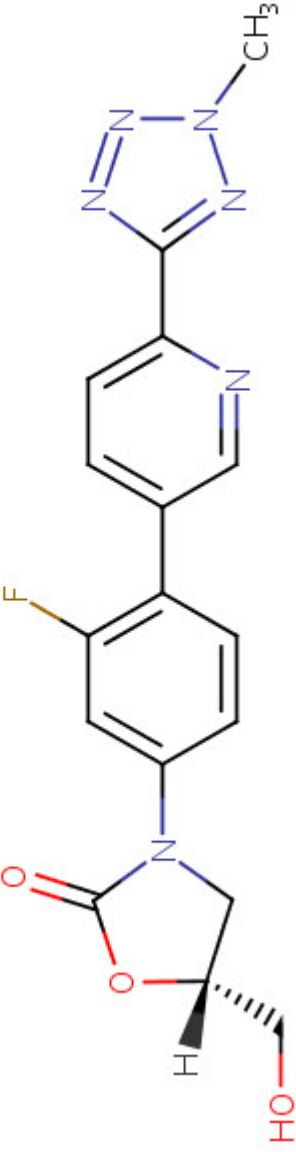
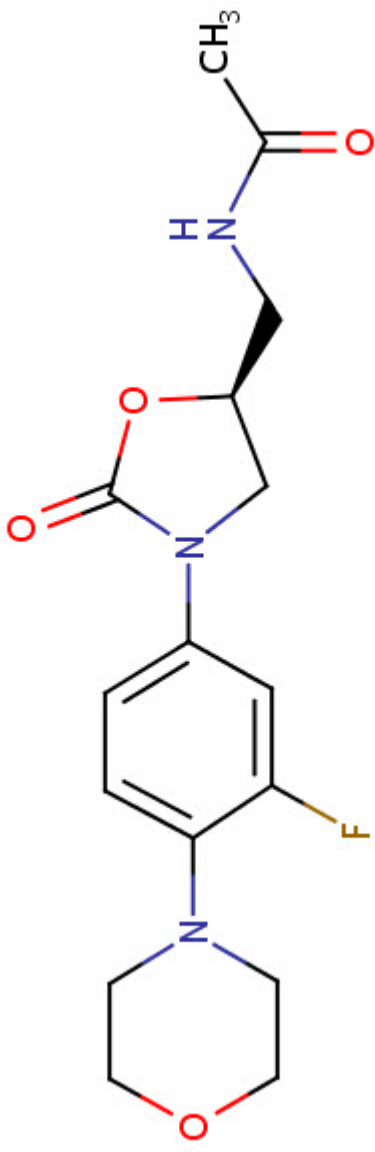
DRUG CLASS

Antiinfective Agents

COMPLETE LABELING

Product labeling at DailyMed, National Library of Medicine, NIH

CHEMICAL FORMULAS AND STRUCTURES

DRUG	CAS REGISTRY NO.	MOLECULAR FORMULA	STRUCTURE
Tedizolid	856866-72-3	C ₁₇ H ₁₅ F-N ₆ O ₃	 <p>The chemical structure of Tedizolid is a complex molecule. It features a central 5-membered imidazolidinone ring. Attached to this ring are: a hydroxyl group (HO) on a wedge, a hydrogen atom (H) on a dash, a 4-fluorophenyl group, and a 4-(4-methyl-1H-imidazol-2-yl)pyridin-2-yl group.</p>
Linezolid	165800-03-3	C ₁₆ H ₂₀ F-N ₃ O ₄	 <p>The chemical structure of Linezolid is a complex molecule. It features a central 5-membered imidazolidinone ring. Attached to this ring are: a 4-fluorophenyl group, a morpholine ring, and a 2-(acetamido)ethyl group.</p>

ANNOTATED BIBLIOGRAPHY

References updated: 2 April 2016

Zimmerman HJ. Hepatic injury from the treatment of infectious and parasitic diseases. In, Zimmerman HJ. Hepatotoxicity: the adverse effects of drugs and other chemicals on the liver. 2nd ed. Philadelphia: Lippincott, 1999. pp 589-637.

(Expert review of hepatotoxicity published in 1999, before the availability of linezolid and tedizolid which are not mentioned).

Moseley RH. Antibacterial and Antifungal Agents. In, Kaplowitz N, DeLeve LD, eds. Drug-induced liver disease. 3rd Edition. Amsterdam: Elsevier, 2013. p. 463-81.

(Review of hepatotoxicity of antibiotics; linezolid and tedizolid are not discussed).

MacDougall C, Chambers HF. Oxazolidinones (Linezolid). Protein synthesis inhibitors; miscellaneous antibacterial agents. In, Brunton LL, Chabner BA, Knollman BC, eds. Goodman & Gilman's the pharmacological basis of therapeutics. 12th ed. New York: McGraw-Hill, 2011, pp. 1537-8.

(Textbook of pharmacology and therapeutics).

Rubinstein E, Cammarata S, Oliphant T, Wunderink R; Linezolid Nosocomial Pneumonia Study Group. Linezolid (PNU-100766) versus vancomycin in the treatment of hospitalized patients with nosocomial pneumonia: a randomized, double-blind, multicenter study. Clin Infect Dis 2001; 32: 402-12. PubMed PMID: 11170948.

(396 patients treated with either linezolid or vancomycin at 90 sites had similar rates of clinical response and side effects; liver tests were abnormal in 1.0% of linezolid vs 1.6% of vancomycin treated patients).

Apodaca AA, Rakita RM. Linezolid-induced lactic acidosis. N Engl J Med 2003; 348: 86-7. PubMed PMID: 12510056.

(52 year old woman developed intractable nausea and vomiting 11 weeks after starting linezolid and was found to have lactic acidosis [9.9 $\mu\text{mol/L}$] which was reversed after stopping drug; no mention of hepatic abnormalities).

Bernard L, Stern R, Lew D, Hoffmeyer P. Serotonin syndrome after concomitant treatment with linezolid and citalopram. Clin Infect Dis 2003; 36: 1197. PubMed PMID: 12715317.

(81 year old man developed severe lactic acidosis, thrombocytopenia and serotonin syndrome 3 weeks after starting linezolid while also taking citalopram [ALT 66 U/L, CPK 766 U/L, lactate 17.5 $\mu\text{mol/L}$, pH 6.9], leading to cardiac arrest and hepatic failure, but no information on liver function or histology were given).

French G. Safety and tolerability of linezolid. J Antimicrob Chemother 2003; 51 (Suppl 2): ii45-53. PubMed PMID: 12730142.

(Review of adverse events reported in clinical trials of linezolid reported similar rates of adverse events to comparative drugs; diarrhea, nausea and headache in 1-5%; abnormal "liver tests" in 1.0% vs 0.3% of controls. In one study ALT elevations occurred in 2.5% with low- and 9.8% with high-dose linezolid, all elevations were mild and reversible, and similar in rate to comparative agents; overall ALT >2 times ULN occurred in 7.4% vs 7.2%; list of serious adverse events includes "hepatitis").

Rubinstein E, Isturiz R, Standiford HC, Smith LG, Oliphant TH, Cammarata S, Hafkin B, et al. Worldwide assessment of linezolid's clinical safety and tolerability: comparator-controlled phase III studies. Antimicrob Agents Chemother 2003; 47: 1824-31. PubMed PMID: 12760854.

- (Safety assessment in 2046 patients who received linezolid vs 2001 on comparator drugs found similar rates of diarrhea [4.3 vs 3.2%], nausea [3.4 vs 2.3%], headache [2.2 vs 1.3%], liver test abnormalities [1.0 vs 0.3%], serious adverse events [11.4 vs 10.6%], and deaths [4.8 vs 4.9%]; two patients on oxacillin-dicloxacillin developed "hepatitis", but no cases described for linezolid cohort).*
- Kopterides P, Papadomichelakis E, Armaganidis A. Linezolid use associated with lactic acidosis. *Scand J Infect Dis* 2005; 37: 153-4. PubMed PMID: 15764207.
- (Elderly man with severe methicillin-resistant staphylococcus aureus infection developed rising lactate [2.0→12.5 μmol/L] over 7 days of linezolid therapy, resolved with discontinuation, no evidence of liver injury).*
- Soriano A, Miró O, Mensa J. Mitochondrial toxicity associated with linezolid. *N Engl J Med* 2005; 353: 2305-6. PubMed PMID: 16306535.
- (Three patients with asthenia and lactic acidosis after 1.5-3 months of linezolid therapy were studied for mitochondrial function in peripheral blood mononuclear cells; complex IV enzymatic activity was decreased).*
- De Vriese AS, Coster RV, Smet J, Seneca S, Lovering A, Van Haute LL, et al. Linezolid-induced inhibition of mitochondrial protein synthesis. *Clin Infect Dis* 2006; 42: 1111-7. PubMed PMID: 16575728.
- (Patient treated with linezolid and rifampicin for 4 months developed loss of vision and lactic acidosis [24.5 μmol/L], renal failure and flaccid paralysis; muscle, liver, kidney and white cells were studied; liver showed micro- and macro-vesicular steatosis, decreased activity and protein of respiratory chain complexes I and IV in mitochondria, but normal mtDNA and morphology by electron microscopy).*
- Jaksic B, Martinelli G, Perez-Oteyza J, Hartman CS, Leonard LB, Tack KJ. Efficacy and safety of linezolid compared with vancomycin in a randomized, double-blind study of febrile neutropenic patients with cancer. *Clin Infect Dis* 2006; 42: 597-607. PubMed PMID: 16447103.
- (Controlled trial of linezolid vs vancomycin for an average of 11 days in 453 patients with cancer and febrile neutropenia found similar safety and efficacy; "the distribution of biochemical test results, including mean values, changes from baseline values and abnormal values, was similar between groups").*
- McKee EE, Ferguson M, Bentley AT, Marks TA. Inhibition of mammalian mitochondrial protein synthesis by oxazolidinones. *Antimicrob Agents Chemother* 2006; 50: 2042-9. PubMed PMID: 16723564.
- (Like chloramphenicol and tetracycline, the oxazolidinones bind to bacterial as well as mitochondrial ribosomes and inhibit protein synthesis, the binding site being conserved between mitochondrial and gram-positive bacteria).*
- Pea F, Scudeller L, Lugano M, Baccarani U, Pavan F, Tavio M, et al. Hyperlactacidemia potentially due to linezolid overexposure in a liver transplant recipient. *Clin Infect Dis* 2006; 42: 434-5. PubMed PMID: 16392096.
- (59 year old liver transplant recipient developed increased lactate levels after 11 days of linezolid therapy, returning to normal with discontinuation; no mention of other liver tests).*
- Narita M, Tsuji BT, Yu VL. Linezolid-associated peripheral and optic neuropathy, lactic acidosis, and serotonin syndrome. *Pharmacotherapy* 2007; 27: 1189-97. PubMed PMID: 17655517.
- (Review and summary of published literature on severe side effects of linezolid).*
- Wiener M, Guo Y, Patel G, Fries BC. Lactic acidosis after treatment with linezolid. *Infection*. 2007; 35: 278-81. PubMed PMID: 17646908.
- (80 year old woman presented with shortness of breath and lactic acidosis after 19 days of linezolid [pH 7.0, lactate 19 μmol/L], with rapid recovery upon switching to daptomycin).*

- Metzgas EI, Falagas ME. Update on the safety of linezolid. *Expt Opin Drug Saf* 2009; 8: 485-91. PubMed PMID: 19538105.
- (Summary of pooled results of clinical trials of linezolid in 2046 patients; severe side effects occurred in 0.4% including cytopenia, neurological side effects and lactic acidosis; ALT elevations also occurred, and "some patients had to discontinue treatment because of these abnormalities").*
- Savard S, Desmeules S, Riopel J, Agharazii M. Linezolid-associated acute interstitial nephritis and drug rash with eosinophilia and systemic symptoms(DRESS) syndrome. *Am J Kidney Dis* 2009; 54: e17-20. PubMed PMID: 19733945.
- (84 year old woman developed pruritus, rash, facial edema and eosinophilia on the 7th day of linezolid therapy with interstitial nephritis and mild hepatitis [AST ~90 U/L, GGT ~105 U/L], with rapid response to prednisone after stopping linezolid).*
- De Bus L, Depuydt P, Libbrecht L, Vandekerckhove L, Nollet J, Benoit D, Vogelaers D, Van Vlierberghe H. Severe drug-induced liver injury associated with prolonged use of linezolid. *J Med Toxicol* 2010; 6: 322-6. PubMed PMID: 20358416.
- (55 year old woman developed jaundice and lactic acidosis after 50 days of linezolid and meropenem therapy [bilirubin 12.1 mg/dL, ALT 113 U/L, Alk P 2486 U/L, pH 7.27, lactate 121 mg/dL], with signs of liver failure, but resolving spontaneously over next 3 months).*
- Carson J, Cerda J, Chae JH, Hirano M, Maggiore P. Severe lactic acidosis associated with linezolid use in a patient with the mitochondrial DNA A2706G polymorphism. *Pharmacotherapy* 2007; 27: 771-4. PubMed PMID: 17461714.
- (35 year old woman developed severe lactic acidosis 35 days after starting linezolid; had mitochondrial DNA polymorphism that may have predisposed her to injury).*
- Scotton P, Fuser R, Torresan S, Carniato A, Giobbia M, Rossi C, Inojosa WO, Vaglia A. Early linezolid-associated lactic acidosis in a patient treated for tuberculous spondylodiscitis. *Infection* 2008; 36: 387-8. PubMed PMID: 18642110.
- (81 year old woman developed acidosis 12 days after starting intravenous linezolid [pH 7.24, lactate 18.6 mmol/L], isoniazid, rifampin and ethambutol for atypical tuberculosis, recovering within a week of stopping and later tolerating isoniazid, pyrazinamide and rifampin).*
- Lee YR, Powell N, Bonatti H, Sawyer RG, Barroso L, Pruett TL, Sifri CD, Volles D. Early development of lactic acidosis with short term linezolid treatment in a renal recipient. *J Chemother* 2008; 20: 766-7. PubMed PMID: 19129081.
- (56 year old woman with urosepsis and renal transplant developed metabolic acidosis which worsened with linezolid therapy, but resolved once it was stopped).*
- Boutoille D, Grossi O, Depatureaux A, Tattevin P. Fatal lactic acidosis after prolonged linezolid exposure for treatment of multidrug-resistant tuberculosis. *Eur J Intern Med* 2009; 20: e134-5. PubMed PMID: 19782904.
- (48 year old man developed lactic acidosis 3 months after starting oral linezolid for resistant tuberculosis [pH 7.32, lactate 11.6 mmol/L], while linezolid was stopped, he was found dead 3 weeks later).*
- Fernández de Orueta L, Díaz V, Ramírez M, Alvarez R. [Linezolid-induced lactic acidosis]. *Enferm Infecc Microbiol Clin* 2009; 27: 550-1. PubMed PMID: 19819595.
- (72 year old woman developed lactic acidosis beginning 34 days after starting linezolid with severe distress by day 39 [pH 6.93, lactate 6.1 mmol/L], resolving rapidly upon stopping).*
- Velez JC, Janech MG. A case of lactic acidosis induced by linezolid. *Nat Rev Nephrol* 2010; 6: 236-42. PubMed PMID: 20348931.

- (36 year old man with end stage renal disease on dialysis developed lactic acidosis 6 weeks after starting oral linezolid for vancomycin resistant Enterococcus fecalis [pH 7.31, lactate 12.5 mmol/L, ALT 89 U/L], resolving within a week of stopping; ribosomal DNA polymorphism 2706A>G found, similar to two cases in the literature).*
- De Bus L, Depuydt P, Libbrecht L, Vandekerckhove L, Nollet J, Benoit D, Vogelaers D, et al. Severe drug-induced liver injury associated with prolonged use of linezolid. *J Med Toxicol* 2010; 6: 322-6. PubMed PMID: 20358416.
- (55 year old woman developed jaundice and itching 6-7 weeks after starting linezolid and meropenem [bilirubin 12.1 mg/dL, ALT 113 U/L, Alk P 2,486 U/L, pH 7.27, lactate 121 mg/dL], with biopsy showing microvesicular steatosis and slowly resolving after stopping antibiotics, the patient later dying of septic shock).*
- Cope TE, McFarland R, Schaefer A. Rapid-onset, linezolid-induced lactic acidosis in MELAS. *Mitochondrion* 2011; 11: 992-3. PubMed PMID: 21907311.
- (21 year old man with mitochondrial encephalomyopathy, lactic acidosis and stroke-like episode syndrome [MELAS] developed tachypnea and rising lactate levels within a day of starting linezolid, rapidly returning to baseline upon stopping).*
- Su E, Crowley K, Carcillo JA, Michaels MG. Linezolid and lactic acidosis: a role for lactate monitoring with long-term linezolid use in children. *Pediatr Infect Dis J* 2011; 30: 804-6. PubMed PMID: 21852764.
- (Three children [0.5, 0.5 and 16 years old], two boys and one girl, with hepatic and/or intestinal insufficiency developed lactic acidosis during extended therapy [53, 31 and 7 days] with oral linezolid, resolving rapidly upon stopping in two, but with progressive acidosis and death in 1 child).*
- Contou D, Fichet J, Grimaldi D, Cariou A. Early life-threatening lactic acidosis following a single infusion of linezolid. *Int J Antimicrob Agents* 2011; 38: 84-5. PubMed PMID: 21482079.
- (81 year old man with chronic hepatitis C on ventilatory support for pneumonia with Enterococcus fecalis superinfection developed lactic acidosis within hours of starting intravenous linezolid [pH 7.03, lactate 16 mmol/L], resolving within hours of stopping).*
- Leach KL, Brickner SJ, Noe MC, Miller PF. Linezolid, the first oxazolidinone antibacterial agent. *Ann N Y Acad Sci* 2011 Mar; 1222: 49-54. PubMed PMID: 21434942.
- (Overview from the sponsor of the discovery, development, mechanism of action, pharmacology, and spectrum of activity of linezolid, the first of a new class of antibiotics).*
- Miyawaki A, Ueda T, Nakao A, Adachi M, Ohya M, Yamada I, Takesue Y, et al. Linezolid-induced lactic acidosis followed by severe hypophosphatemia after discontinuation of linezolid. *Surg Infect (Larchmt)* 2013; 14: 229-30. PubMed PMID: 23464676.
- (75 year old man developed lactic acidosis 72 days after starting oral linezolid [pH 7.09, lactate >25 mmol/L], developing severe hypophosphatemia, but ultimately recovering completely; no mention of liver injury).*
- Holmaas G, Lærum JH, Schjøtt J, Leiva RA. A man in his seventies with a long-term infection and severe acid-base imbalance. *Tidsskr Nor Laegeforen* 2014; 134: 315-319. PubMed PMID: 24518482.
- (70 year old man developed lactic acidosis while on long term linezolid [bilirubin not given, ALT 1080 U/L, Alk P normal, INR >7.5, pH 7.03, lactate 27 mmol/L], with prompt improvement on stopping drug).*
- Prokocimer P, De Anda C, Fang E, Mehra P, Das A. Tedizolid phosphate vs linezolid for treatment of acute bacterial skin and skin structure infections: the ESTABLISH-1 randomized trial. *JAMA* 2013; 309: 559-69. PubMed PMID: 23403680.

(Among 667 adults with acute bacterial skin or skin-structure infections treated with tedizolid [200 mg daily for 6 days] vs linezolid [600 mg twice daily for 10 days], response rates were similar as were adverse events, ALT elevations above twice normal occurred in 4.1% vs 3.5%).

Das D, Tulkens PM, Mehra P, Fang E, Prokocimer P. Tedizolid phosphate for the management of acute bacterial skin and skin structure infections: safety summary. Clin Infect Dis 2014; 58 Suppl 1 S51-7. PubMed PMID: 24343833.

(Review of the safety of tedizolid as short term therapy of acute bacterial skin or skin-structure infectious summarizing results from Prokocimer [2013] and Moran [2014]).

Kisgen JJ, Mansour H, Unger NR, Childs LM. Tedizolid: a new oxazolidinone antimicrobial. Am J Health Syst Pharm 2014; 71: 621-33. PubMed PMID: 24688035.

(Review of the mechanism of action, pharmacokinetics, efficacy and safety of tedizolid; no mention of ALT elevations or hepatotoxicity).

Moran GJ, Fang E, Corey GR, Das AF, De Anda C, Prokocimer P. Tedizolid for 6 days versus linezolid for 10 days for acute bacterial skin and skin-structure infections (ESTABLISH-2): a randomised, double-blind, phase 3, non-inferiority trial. Lancet Infect Dis 2014; 14: 696-705. PubMed PMID: 24909499.

(Among 666 patients with acute bacterial skin or skin-structure infections treated with tedizolid [200 mg intravenous once daily for 6 days] or linezolid [600 mg twice daily by mouth for 10 days], response rates were similar while gastrointestinal side effects were less with tedizolid; no mention of ALT elevations or hepatotoxicity).

Two new drugs for skin and skin structure infections. Med Lett Drugs Ther 2014; 56 (1449): 73-5. PubMed PMID: 25118799.

(Concise review of mechanism of action, efficacy, safety and costs of tedizolid shortly after its approval in the US mentions that common side effects include nausea, headache, diarrhea, vomiting and dizziness, and potentially severe effects include optic and peripheral neuropathy, similar to linezolid).

Zhanel GG, Love R, Adam H, Golden A, Zelenitsky S, Schweizer F, Gorityala B, et al. Tedizolid: a novel oxazolidinone with potent activity against multidrug-resistant gram-positive pathogens. Drugs 2015; 75: 253-70. PubMed PMID: 25673021.

(Review of the structure, mechanism of action, antibacterial spectrum, bacterial resistance, efficacy and safety of tedizolid mentions a study of tedizolid in healthy controls of ascending doses given for 21 days in which one subject developed ALT elevations of more than twice normal after 11 days, that resolved rapidly upon stopping).

Flanagan S, Minassian SL, Morris D, Ponnuraj R, Marbury TC, Alcorn HW, Fang E, Prokocimer P. Pharmacokinetics of tedizolid in subjects with renal or hepatic impairment. Antimicrob Agents Chemother 2014; 58: 6471-6. PubMed PMID: 25136024.

(Analysis of the pharmacokinetics of single doses of tedizolid in patients with mild and moderate hepatic dysfunction found minimally altered plasma levels, the total area under the curve being increased by 22-34%).