



## Phenobarbital

Updated: January 15, 2014.

## OVERVIEW

### Introduction

Phenobarbital is a barbiturate that is widely used as a sedative and an antiseizure medication. Phenobarbital has been linked to rare instances of idiosyncratic liver injury that can be severe and even fatal.

### Background

Phenobarbital (fee" noe bar' bi tal) is a barbiturate and is believed to act as a nonselective depressant. Phenobarbital also has anticonvulsant activity and is believed to act by suppressing spread of seizure activity by enhancing the effect of gamma aminobutyric acid (GABA), raising the seizure threshold. Phenobarbital was introduced into clinical medicine in 1911 but was never subjected to critical controlled studies to demonstrate safety and efficacy. For these reasons, phenobarbital is now considered of unproven benefit in controlling seizures. Nevertheless, it is commonly used for prevention and management of partial and generalized seizures, usually as an adjunctive agent in combination with other anticonvulsants. Phenobarbital is also used for sedation and insomnia although its use for these conditions is now uncommon. Phenobarbital is also used in fixed combinations with other antispasmodics or anticholinergic agents and used for gastrointestinal complaints, including irritable bowel syndrome. The typical starting dose in treating seizures in adults is 60 to 100 mg in three divided doses daily. Oral formulations of tablets or capsules of 15, 16, 30, 60, 90 and 100 mg are available in multiple generic forms. Parenteral formations and oral elixirs for pediatric use are also available. Frequent side effects include drowsiness, sedation, hypotension, and skin rash.

### Hepatotoxicity

Prospective studies suggest that less than 1% of subjects develop elevations in serum aminotransferase levels during long term phenobarbital therapy. Clinically apparent hepatotoxicity from phenobarbital is rare but can be abrupt in onset, severe and even fatal. Phenobarbital hepatotoxicity typically occurs in the setting of anticonvulsant hypersensitivity syndrome with onset of fever, rash, facial edema, lymphadenopathy, elevations in white count and eosinophilia occurring 1 week to several months after starting therapy. Liver involvement is common, but is usually mild and anicteric and overshadowed by other features of hypersensitivity (rash, fever). In some cases, hepatic involvement is more prominent with marked elevations in serum enzyme levels, jaundice and even signs of hepatic failure. The typical enzyme elevations are usually mixed, but can be hepatocellular or cholestatic. Liver biopsy shows mixed hepatitis-cholestatic injury with prominence of eosinophils and occasionally granulomata.

## Mechanism of Injury

The mechanism of phenobarbital hepatotoxicity is thought to be hypersensitivity or an immunological response to a metabolically generated drug-protein complex.

## Outcome and Management

Phenobarbital hepatotoxicity is usually rapidly reversible with improvements beginning within 5 to 7 days of stopping the drug and being complete within 1 to 2 months. In cases of severe injury, progression to acute liver failure and death can occur. Corticosteroids have been used but with uncertain effectiveness. Prolonged cholestasis, but not chronic injury or vanishing bile duct syndrome from phenobarbital therapy, has not been reported. Cross reactivity with other aromatic anticonvulsants (phenytoin, carbamazepine, primidone, and lamotrigine) is common but not invariable. Patients with hypersensitivity to phenobarbital should be monitored carefully if they are to start other aromatic anticonvulsants.

Drug Class: [Anticonvulsants](#), [Sedatives and Hypnotics](#)

## PRODUCT INFORMATION

### REPRESENTATIVE TRADE NAMES

Phenobarbital – Generic, Luminal® Sodium

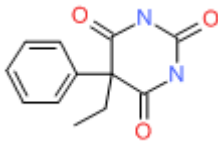
### DRUG CLASS

Anticonvulsants

### COMPLETE LABELING

Product labeling at [DailyMed](#), National Library of Medicine, NIH

## CHEMICAL FORMULA AND STRUCTURE

| DRUG          | CAS REGISTRY NUMBER | MOLECULAR FORMULA | STRUCTURE  |
|---------------|---------------------|-------------------|--|
| Phenobarbital | 50-06-6             | C12-H12-N2-O3     |  |

## ANNOTATED BIBLIOGRAPHY

References updated: 15 January 2014

Zimmerman HJ. Anticonvulsants. In, Zimmerman, HJ. Hepatotoxicity: the adverse effects of drugs and other chemicals on the liver. 2nd ed. Philadelphia: Lippincott, 1999: pp. 498-516.

*(Expert review of anticonvulsants and liver injury published in 1999; mentions that liver injury from phenobarbital is rare, but it has been implicated in at least 15 cases of clinically apparent injury, both hepatocellular and cholestatic).*

- Pirmohamed M, Leeder SJ. Anticonvulsant agents. In, Kaplowitz N, DeLeve LD, eds. Drug-induced liver disease. 3rd ed. Amsterdam: Elsevier, 2013: pp 423-41. (*Review of anticonvulsant induced liver injury mentions that clinically apparent hepatotoxicity from phenobarbital is rare and that cross sensitivity to hepatic injury from other aromatic anticonvulsants occurs, but is not invariable*).
- McNamara JO. Pharmacology of the epilepsies. In, Brunton LL, Chabner BA, Knollman BC, eds. Goodman & Gilman's the pharmacological basis of therapeutics. 12th ed. New York: McGraw-Hill, 2011, pp. 583-608. (*Textbook of pharmacology and therapeutics*).
- Birch CA. Jaundice due to phenobarbital. Lancet 1936; i: 478-9. Welton DG. Exfoliative dermatitis and hepatitis due to phenobarbital. JAMA 1950; 143: 232-4. PubMed PMID: 15415251.  
(25 year old pregnant woman developed rash, followed by facial and peripheral edema, itching, erythema, desquamation, and high fever 6 weeks after starting phenobarbital [white blood count 73,000, 32% eosinophils], jaundiced for a few weeks but ultimately recovered).
- McGeachy TE, Bloomer WE. The phenobarbital sensitivity syndrome. Am J Med 1953; 14: 600-4. PubMed PMID: 13040367.  
(3 cases of severe phenobarbital reactions seen between 1933 and 1947; two men and one woman, ages 27 to 41 years, developing rash, desquamation, fever, delirium and jaundice within 1-2 weeks of starting drug; one instance was fatal).
- Pagliario L, Campesi G, Aguglia F. Barbiturate jaundice. Report of a case due to a barbiturate-containing drug, with positive rechallenge to phenobarbital. Gastroenterology 1969; 56: 938-43. PubMed PMID: 4238546.  
(31 year old woman developed rash, fever, facial edema after 2 doses of "barbital" and by 7 days developed jaundice [bilirubin 24.1 mg/dL, ALT 200 U/L, ALP 15 BU] which was prolonged; rechallenge with phenobarbital caused recurrence of fever, rash and jaundice [19 mg/dL]; three biopsies were done, but vanishing bile duct syndrome was evidently not present).
- Weisburst M, Self T, Peace R, Cooper J. Jaundice and rash associated with the use of phenobarbital and hydrochlorothiazide. South Med J 1976; 69: 126-7. PubMed PMID: 128822.  
(18 year old woman developed rash followed by fever, anorexia, lymphadenopathy and jaundice [bilirubin 7.2 mg/dL, AST 250 U/L, ALP 350 U/L], rapid resolution although no mention of drug being stopped).
- Evans WE, Self TH, Weisburst MR. Phenobarbital-induced hepatic dysfunction. Drug Intell Clin Pharm 1976; 10: 439-43. Not in PubMed
- Thirunavukkaram S, Merk P, Fitzgerald JF. Near-fatal phenobarbital hepatotoxicity in an 8 year old male. Gastroenterology 1979; 76: 1261. Not in PubMed
- Shapiro PA, Antonioli DA, Peppercorn MA. Barbiturate-induced submassive hepatic necrosis. Am J Gastroenterol 1980; 74: 270-3. PubMed PMID: 7468565.  
(71 year old woman developed rash on phenytoin and was switched to phenobarbital and 3 months later developed anorexia, fatigue persisting for 6 weeks to onset of jaundice [bilirubin 5.3 mg/dL, ALT 837 U/L, ALP 320 U/L], improved slowly but relapsed with restarting phenobarbital; biopsy showed submassive necrosis, ultimately recovering completely; no features of hypersensitivity).
- Jacobi G, Thorbeck R, Ritz A, Janssen W, Schmidts HL. Fatal hepatotoxicity in child on phenobarbitone and sodium valproate. Lancet 1980; 1: 712-3. PubMed PMID: 6103126.

- (Child given valproate [36 mg/kg] and phenobarbital for 3 months developed confusion and coma [bilirubin 9.7 mg/dL, ALT 60 U/L, high ammonia and protime], ultimately dying; more likely due to valproate than phenobarbital hepatotoxicity).*
- Spielberg SP, Gordeon GB, Blake DA, Goldstein DA, Herlong HF. Predisposition to phenytoin hepatotoxicity assessed in vitro. *N Engl J Med* 1981; 305: 722-7. PubMed PMID: 6790991.
- (3 patients with phenytoin hepatotoxicity had dose dependent cytotoxicity of lymphocytes exposed to microsomal metabolized drug [arene oxides]; clinical onset arose 4, 4 and 1 week after starting phenytoin, with rash, fever and jaundice; [bilirubin 7.8, 11.5 and 0.5 g/dL, AST 790, 2340 and 62 U/L, eosinophils 9%, 10% and 10%], all 3 recovered).*
- Lane T, Peterson EA. Hepatitis as a manifestation of phenobarbital hypersensitivity. *South Med J* 1984; 77: 94. PubMed PMID: 6695234.
- (4 year old boy developed fever and rash about 1 week after starting phenobarbital and 1 week later found to have ALT 273 U/L [no bilirubin reported], rapid improvement with stopping).*
- Knutsen AP, Anderson J, Satayaviboon S, Slavin RG. Immunologic aspects of phenobarbital hypersensitivity. *J Pediatr* 1984; 105: 558-63. PubMed PMID: 6332892.
- (Seven patients with onset of hypersensitivity 2 to 23 days after starting phenobarbital with fever and a pruritic rash which was confluent and desquamating; 2 patients had abnormal liver tests, but without jaundice; 3 had eosinophilia, 3 IgE elevations; 2 decreased C4 levels; several had positive lymphocyte stimulation tests to phenytoin or phenobarbital).*
- Fonseca JC, Azulay DR, Rozembau I, Azulay RD. [Hypersensitivity syndrome caused by phenytoins and phenobarbital] *Med Cutan Ibero Lat Am* 1984; 12: 187-92. Portuguese. PubMed PMID: 623723.
- Kahn HD, Faguet GB, Agee JF, Middleton HM. Drug-induced liver injury. In vitro demonstration of hypersensitivity to both phenytoin and phenobarbital. *Arch Intern Med* 1984; 144: 1677-9. [PubMed Citation](#)
- (16 year old girl developed fever, facial edema, lymphadenopathy and rash 3 weeks after starting phenobarbital and phenytoin; stopping phenytoin had no effect, but she improved with stopping phenobarbital and had positive lymphocyte stimulation tests to both).*
- Palomeque A, Doménech P, Martínez-Gutiérrez A, Lequerica P. [Severe hypersensitivity to phenobarbital with erythema multiforme, cholestatic hepatitis and aplastic anemia] *An Esp Pediatr* 1986; 24: 328-30. Spanish. PubMed PMID: 3740671.
- (11 year old girl developed rash, fever, adenopathy, somnolence and facial edema 4 weeks after starting phenobarbital [bilirubin 6.7 to 42.8 mg/dL, ALK 1380 to 2980 U/L, Alk P 855 to 3146 U/L], with confluent necrosis and central collapse on liver biopsy, transient episode of aplastic anemia during recovery).*
- Shear NH, Spielberg SP. Anticonvulsant hypersensitivity syndrome: in vitro assessment of risk. *J Clin Invest* 1988; 82: 1826-32. PubMed PMID: 3198757.
- (Lymphocyte cytotoxicity found in response to drug metabolites from 53 patients with hypersensitivity to anticonvulsants, including 35/36 to phenytoin, 22/27 to phenobarbital and 25/27 to carbamazepine; 51% had hepatitis).*
- Roberts EA, Spielberg SP, Goldbach M, Phillips MJ. Phenobarbital hepatotoxicity in an 8-month-old infant. *J Hepatol* 1990; 10: 235-9. PubMed PMID: 2332596.
- (8 month old boy with seizures given phenobarbital for 2 weeks developed rash followed by fever with eosinophilia, atypical lymphocytes and jaundice [bilirubin 2.9 mg/dL, ALT 430 U/L, Alk P 135 U/L], slow recovery, positive lymphocyte cytotoxicity test).*

Horsmans Y, Larrey D, Pessayre D, Rueff B, Degott C, Benhamou JP. [Atrium-related hepatitis. Report of four cases] *Gastroenterol Clin Biol* 1991; 15: 648-52. PubMed PMID: 1684328.

*(Atrium is a combination of phenobarbital and two carbamates; 4 cases of hepatotoxicity arising 1-4 months after starting Atrium [normal bilirubin, ALT 1.5-21 fold elevated] with mild symptoms of asthenia, but no fever or rash and resolving within 1-3 months of stopping).*

Pariante EA, Mineur D. [Atrium-induced hepatitis with autoimmune pattern] *Gastroenterol Clin Biol* 1992; 16: 485-6. PubMed PMID: 1526409.

*(Patient developed fatigue one month after starting Atrium and clomethacine [bilirubin normal, ALT 16.5 times ULN, GGT 10 times ULN, ANA 1:160], resolved with stopping but recurrence of fatigue, ALT elevation and ANA/SMA positivity with two rechallenges: HLA A1, A9, B8, B27).*

Handfield-Jones SE, Jenkins RE, Whittaker SJ, Besse CP, McGibbon DH. The anticonvulsant hypersensitivity syndrome. *Br J Dermatol* 1993; 129: 175-7. PubMed PMID: 7654579.

*(3 cases of fever and rash arising 3, 4 and 10 weeks after starting phenytoin or carbamazepine; two required steroids; only 1 had hepatitis; one died of multiorgan failure, others switched to valproate or clobazam without recurrence).*

Brocheriou I, Zafrani ES, Mavier P. [Severe acute hepatitis caused by Atrium] *Gastroenterol Clin Biol* 1993; 17: 305-6. PubMed PMID: 8339895.

*(29 year old man developed jaundice after 7 months of Atrium therapy [also on valproate and phenobarbital] with abdominal pain and jaundice [bilirubin 10 mg/dL, ALT 200-4056 U/L, ANA 1:200], biopsy showed no fat, recurrence with rechallenge of Atrium, but not valproate).*

Horsmans Y, Lannes D, Pessayre D, Larrey D. Possible association between poor metabolism of mephenytoin and hepatotoxicity caused by Atrium, a fixed combination preparation containing phenobarbital, febarbamate and ifebarbamate. *J Hepatol* 1994; 21: 1075-9. PubMed PMID: 7699230.

*(Hydroxylation index of mephenytoin [CYP 2C] was assessed in 24 patients with drug induced hepatitis, found index higher [12.4] in 3 patients with Atrium hepatitis than in controls [1.8] and other patients [2.5], attributed abnormality to a defect in mephenytoin oxidation).*

Di Martino V, Mallat A, Duvoux C, Zafrani ES, Dhumeaux D. [Severe hepatitis caused by phenobarbital] *Gastroenterol Clin Biol* 1994; 18: 904-5. PubMed PMID: 7875406.

*(Patient on phenobarbital for 1 month developed fever and rash followed by adenopathy and jaundice [bilirubin 8.7 mg/dL, ALT 22 times ULN, elevated protime], treated with prednisone and recovered within 1 month).*

Schneider S, Charles F, Chichmanian RM, Montoya ML, Rampal P. [Acute hepatitis associated with microvesicular steatosis induced by Atrium] *Gastroenterol Clin Biol* 1995; 19: 1064-5. PubMed PMID: 8729422.

*(37 year woman developed abdominal pain 6 months after starting Atrium [bilirubin 2.0 mg/dL, ALT 9 times ULN, Alk P 0.8 times ULN, ANA 1:1000], biopsy showed microvesicular fat; also taking carbimazole and phenytoin).*

Cayla JM, Fandi L, Arnould P, Degott C, Gouffier E. [Atrium 300 hepatitis. A new case] *Presse Med* 1995; 24: 1665. PubMed PMID: 8545391.

*(65 year old woman was found to have ALT elevations [5 times ULN] 3 months after starting Atrium, with rapid resolution on stopping and recurrence with rechallenge; no jaundice but some fatigue).*

Wallace SJ. A comparative review of the adverse effects of anticonvulsants in children with epilepsy. *Drug Saf* 1996; 15: 378-93. PubMed PMID: 8968693.

*(Systematic review; ALT elevations occur in 4% of children on phenytoin, 6% on valproate, 1% on carbamazepine but not with phenobarbital; skin rash and Stevens-Johnson syndrome discussed related to phenobarbital).*

Schlienger RG, Shear NH. Antiepileptic drug hypersensitivity syndrome. *Epilepsia* 1998; 39 Suppl 7: S3-7. PubMed PMID: 9798755.

*(Review of anticonvulsant hypersensitivity syndrome; onset 2-8 weeks after starting therapy with aromatic anticonvulsants presenting with high fever, rash, adenopathy and pharyngitis followed by organ involvement, most commonly the liver [~50%], but also hematologic, renal or pulmonary; eosinophilia, blood dyscrasias, nephritis; sometimes facial edema, oral ulcers, hepatosplenomegaly, myopathy, disseminated intravascular coagulation, atypical lymphocytosis; rash usually exanthema with pruritus, occasional follicular pustules or exfoliative dermatitis and erythroderma, erythema multiforme, Stevens-Johnson syndrome or toxic epidermal necrolysis).*

Knowles SR, Shapiro LE, Shear NH. Anticonvulsant hypersensitivity syndrome: incidence, prevention and management. *Drug Saf* 1999; 21: 489-501. PubMed PMID: 10612272.

*(Review of anticonvulsant hypersensitivity syndrome: triad of fever, rash and internal organ injury occurring 1-8 weeks after exposure to anticonvulsant; liver being most common internal organ involved. Occurs in 1:1000-1:10,000 initial exposures to phenytoin, carbamazepine, phenobarbital or lamotrigine, unrelated to dose, perhaps predisposed by valproate; liver injury arises 1-4 weeks after onset of rash and ranges in severity from asymptomatic ALT elevations to icteric hepatitis to acute liver failure. High mortality rate with jaundice; other organs include muscle, kidney, brain, heart and lung. Pseudolymphoma syndrome and serum sickness-like syndrome are separate complications of anticonvulsants. Role of corticosteroids uncertain; cross reactivity among the agents should be assumed).*

Lachgar T, Touil Y. [The drug hypersensitivity syndrome or DRESS syndrome to phenobarbital] *Allerg Immunol (Paris)* 2001; 33: 173-5. PubMed PMID: 11434197.

*(78 year old woman developed rash and fever 3 weeks after starting phenobarbital [ALT 3 times ULN, eosinophilia], resolving within a month of stopping).*

Turner RB, Kim CC, Streams BN, Culpepper K, Haynes HA. Anticonvulsant hypersensitivity syndrome associated with Bellamine S, a therapy for menopausal symptoms. *J Am Acad Dermatol* 2004; 50 (5 Suppl): S86-9.

*(Patient developed fever, rash and facial edema followed by jaundice 2 months after starting Bellamine S which contains phenobarbital, belladonna and ergotamine [bilirubin 2.4 mg/dL, ALT 97 U/L, Alk P 160 U/L, 14% eosinophils], and then developed complications of herpes zoster and meningitis during prednisone therapy for the hypersensitivity, and later had recurrence during carbamazepine therapy for neuralgia).*

Autret-Leca E, Norbert K, Bensouda-Grimaldi L, Jonville-Béra AP, Saliba E, Bentata J, Barthez-Carpentier MA. [DRESS syndrome, a drug reaction which remains bad known from paediatricians] *Arch Pediatr* 2007; 14: 1439-41. PubMed PMID: 17997290.

*(6 year old girl with epilepsy developed rash and fever 3 weeks after starting phenobarbital with eosinophilia [ALT 5 times ULN, Alk P 1.5 times ULN], improving clinically with corticosteroid therapy; switched to topiramate and valproate without recurrence).*

Tohyama M, Hashimoto K, Yasukawa M, et al. Association of human herpes virus 6 reactivation with the flaring and severity of drug-induced hypersensitivity syndrome. *Br J Dermatol* 2007; 157: 934-40. PubMed PMID: 17854362.

*(Anti-HHV-6 testing of 100 patients with drug induced hypersensitivity syndrome [34% with hepatitis] found rise in IgG levels in 62 patients, largely in more severe cases; HHV-6 DNA detected in 18; drugs included carbamazepine, phenobarbital, phenytoin, allopurinol, sulfasalazine and mexiletine).*

Di Mizio G, Gambardella A, Labate A, Perna A, Ricci P, Quattrone A. Hepatonecrosis and cholangitis related to long-term phenobarbital therapy: an autopsy report of two patients. *Seizure* 2007; 16: 653-6. PubMed PMID: 17574447.

*(Two men, ages 44 and 40 years, on long term phenobarbital had sudden death and were found to have granulomas and portal inflammation on autopsy).*

Björnsson E. Hepatotoxicity associated with antiepileptic drugs. *Acta Neurol Scand* 2008; 118: 281-90. PubMed PMID: 18341684.

*(Review of all anticonvulsants; phenytoin hepatotoxicity usually occurs as a part of a hypersensitivity syndrome, in 1:10,000 to 1:50,000 persons, 100 published cases, mean onset at 4 weeks, 13% mortality; in contrast, phenobarbital has only rarely been reported to cause liver injury).*

Chalasanani N, Fontana RJ, Bonkovsky HL, Watkins PB, Davern T, Serrano J, Yang H, Rochon J; Drug Induced Liver Injury Network (DILIN). Causes, clinical features, and outcomes from a prospective study of drug-induced liver injury in the United States. *Gastroenterology* 2008; 135: 1924-34. PubMed PMID: 18955056.

*(Among 300 cases of drug induced liver disease in the US collected between 2004 and 2008, 18 cases were attributed to anticonvulsants, no case was attributed to phenobarbital).*

Ferrajolo C, Capuano A, Verhamme KM, Schuemie M, Rossi F, Stricker BH, Sturkenboom MC. Drug-induced hepatic injury in children: a case/non-case study of suspected adverse drug reactions in VigiBase. *Br J Clin Pharmacol* 2010; 70: 721-8. [PubMed Citation](#) (Worldwide pharmacovigilance database contained 9036 hepatic adverse drug reactions in children, phenobarbital accounting for 41 cases [0.4%]

*for an adjusted odds ratio of 6.6).*

Molleston JP, Fontana RJ, Lopez MJ, Kleiner DE, Gu J, Chalasanani N; for the Drug-Induced Liver Injury Network. Characteristics of idiosyncratic drug-induced liver injury in children: results from the DILIN Prospective Study. *J Pediatr Gastroenterol Nutr* 2011; 53: 182-9. [PubMed Citation](#)

*(Among 30 children with drug induced liver injury enrolled in a prospective US database between 2004 and 2008, 8 were due to anticonvulsants [lamotrigine in 3, valproate in 3, phenytoin in 1 and carbamazepine in 1], none were attributed to phenobarbital).*

Zhang LL, Zeng LN, Li YP. Side effects of phenobarbital in epilepsy: a systematic review. *Epileptic Disord* 2011; 13: 349-65. PubMed PMID: 21926048.

*(Review of the side effects of phenobarbital focusing upon cognitive effects).*

Drugs for epilepsy. *Treat Guidel Med Lett*. 2013 Feb;11 (126):9-18. PubMed 23348233 PubMed PMID: 23348233.

*(Concise review and guidelines to use of anticonvulsants; phenobarbital is listed under "other drugs" and said to be effective for partial and secondarily generalized tonic-clonic seizures; no mention of hepatotoxicity).*