



Oxcarbazepine

Updated: January 27, 2014.

OVERVIEW

Introduction

Oxcarbazepine is a keto analogue of carbamazepine and, like the parent drug, is a potent anticonvulsant used alone or in combination with other agents in the therapy of partial seizures. Oxcarbazepine has been linked to rare instances of clinically apparent acute drug induced liver injury which resembles carbamazepine hepatotoxicity.

Background

Oxcarbazepine (ox" kar baz' e peen) is a keto analog of carbamazepine and functions as a prodrug being rapidly converted to 10-hydroxycarbamazepine. Oxcarbazepine and carbamazepine are iminostilbenes related chemically to the tricyclic antidepressants and unrelated in structure to most other anticonvulsants. They appear to act by suppression of spread of seizure activity by reduction in the posttetanic potentiation of synaptic transmission. Oxcarbazepine was approved for use in epilepsy in the United States in 2000 and remains in common use. Oxcarbazepine is indicated for prevention and management of partial, complex, mixed and generalized seizures and is commonly used alone or in combination with other anticonvulsants. It is used off-label to treat bipolar disorder. Oxcarbazepine is available as tablets of 150, 300 and 600 mg generically and under the commercial name of Trileptal and as an extended release form under the name Oxtellar XR. Oral formulations for use in children are also available. The recommended starting dose in adults is 300 mg twice daily followed by increases at weekly intervals based upon clinical response, the usual final dose being 600 mg twice daily. Frequent side effects include drowsiness, sedation, ataxia, blurred vision, nausea, vomiting, and skin rash.

Hepatotoxicity

Chronic therapy with oxcarbazepine is associated with elevations in serum aminotransferase levels in a small proportion of patients. These elevations are rarely clinically significant and do not usually require dose modification. Clinically apparent hepatotoxicity from oxcarbazepine is uncommon but described, and is probably less common than occurs with carbamazepine. Oxcarbazepine hepatotoxicity can occur in the setting of anticonvulsant hypersensitivity syndrome with onset of fever, followed by rash, facial edema, lymphadenopathy, elevations in white count and eosinophilia 2 to 8 weeks after starting therapy. The liver involvement ranges from a mild and transient elevation in serum enzymes to abrupt onset of an acute hepatitis-like syndrome, that can be severe and even fatal. The typical enzyme elevations are usually mixed, but can be either hepatocellular or cholestatic. Liver biopsy shows mixed necroinflammatory-cholestatic injury with prominence of eosinophils and occasionally granulomas.

Mechanism of Injury

The mechanism of oxcarbazepine hepatotoxicity appears to be hypersensitivity or an immunological response to a metabolically generated drug-protein complex. Oxcarbazepine like other aromatic anticonvulsants may also trigger acute porphyria by inducing delta- aminolevulinic acid (ALA) synthetase activity. It also induces CYP 3A4 and inhibits CYP 2C19 and can cause drug-drug interactions particularly with other drugs used for epilepsy that induce CYP 3A4 such as phenytoin and phenobarbital.

Outcome and Management

Oxcarbazepine and carbamazepine hepatotoxicity is usually rapidly reversible with stopping therapy, improvements beginning within days. In cases of severe injury, progression to acute liver failure and death can occur. Corticosteroids have been used but with uncertain effectiveness. Cross reactivity with other aromatic anticonvulsants (carbamazepine, phenytoin, phenobarbital, primidone, and lamotrigine) is common, but not invariable. Patients with severe hypersensitivity to oxcarbazepine should avoid exposure to other aromatic anticonvulsants and be switched instead to agents such as a benzodiazepine, valproate, levetiracetam, gabapentin or pregabalin.

Drug Class: [Anticonvulsants](#); see also [Carbamazepine](#)

PRODUCT INFORMATION

REPRESENTATIVE TRADE NAMES

Oxcarbazepine – Generic, Trileptal®

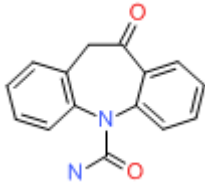
DRUG CLASS

Anticonvulsants

COMPLETE LABELING

Product labeling at DailyMed, National Library of Medicine, NIH

CHEMICAL FORMULA AND STRUCTURE

DRUG	CAS REGISTRY NUMBER	MOLECULAR FORMULA	STRUCTURE
Oxcarbazepine	28721-07-5	C ₁₅ -H ₁₂ -N ₂ -O ₂	 The chemical structure of Oxcarbazepine is a tricyclic system. It consists of a central seven-membered ring containing a nitrogen atom. This central ring is fused to two benzene rings. The nitrogen atom in the central ring is also bonded to a carbonyl group (C=O) and another nitrogen atom, which is in turn bonded to another carbonyl group (C=O).

ANNOTATED BIBLIOGRAPHY

References updated: 27 January 2014

See also references for [Carbamazepine](#).

Zimmerman HJ. Anticonvulsants. In, Zimmerman, HJ. Hepatotoxicity: the adverse effects of drugs and other chemicals on the liver. 2nd ed. Philadelphia: Lippincott, 1999: pp. 498-516.

(Expert review of anticonvulsants and liver injury published in 1999; oxcarbazepine is not discussed).

Pirmohamed M, Leeder SJ. Anticonvulsant agents. In, Kaplowitz N, DeLeve LD, eds. Drug-induced liver disease. 3rd ed. Amsterdam: Elsevier, 2013: pp 423-41. *(Review of anticonvulsant induced liver injury mentions that*

oxcarbazepine undergoes less oxidative metabolism than carbamazepine and is a less potent P450 enzyme inducer; cross reactivity between the 2 drugs is estimated to be 25%).

McNamara JO. Pharmacology of the epilepsies. In, Brunton LL, Chabner BA, Knollman BC, eds. Goodman & Gilman's the pharmacological basis of therapeutics. 12th ed. New York: McGraw-Hill, 2011, pp. 583-608.

(Textbook of pharmacology and therapeutics).

Mitchell MC, Boitnott JK, Arregui A, Maddrey WC. Granulomatous hepatitis associated with carbamazepine therapy. Am J Med 1981; 71: 733-5. PubMed PMID: 7282758.

(Two men, ages 52 and 54 years, developed dark urine 3 weeks after starting carbamazepine, both with fever but no rash or eosinophilia [bilirubin 1.5 and 3.4 mg/dL, ALT 61 and 145 U/L, Alk P 80 and 236 U/L], biopsies showed granulomatous inflammation; both recovered within 4 weeks).

Levy M, Goodman MW, Van Dyne BJ, Sumner HW. Granulomatous hepatitis secondary to carbamazepine. Ann Intern Med 1981; 95: 64-5. PubMed PMID: 7247130.

(Three patients developed fever, fatigue and abdominal pain 3-4 weeks after starting carbamazepine [bilirubin normal to 3.2 mg/dL, AST 20, 95 and 38 U/L, Alk P 1.5-2x ULN, no eosinophilia], biopsies showed granulomas; rechallenge in one led to immediate appearance of fever and rash; rapid recovery).

Hopen G, Nesthus I, Laerum OD. Fatal carbamazepine-associated hepatitis. Report of two cases. Acta Med Scand 1981; 210: 333-5. (PubMed PMID: 7315533.

Two women, ages 23 and 37 years, developed rash and fever followed by jaundice 8 days after starting carbamazepine [peak bilirubin 7.9 and 14.0 mg/dL GGT 5350 and 205 U/L, ALT unknown and 1325 U/L], both had progressive liver failure and died; autopsies showed massive necrosis).

Yeung Laiwah AC, Rapeport WG, Thompson GG, et al. Carbamazepine-induced non-hereditary acute porphyria. Lancet 1983; 1: 790-2. (PubMed PMID: 6132132.

Two patients on high doses of carbamazepine had decreased uroporphyrinogen I synthase [URO-S] and elevated δ aminolevulinic acid levels, and 1 developed symptoms of acute intermittent porphyria; cohort of patients on carbamazepine had slightly reduced levels of URO-S).

Perucca E, Hedges A, Makki KA, Ruprah M, Wilson JF, Richens A. A comparative study on the relative enzyme inducing properties of anticonvulsant drugs in epileptic patients. Br J Clin Pharmacol 1984; 18: 401-10. PubMed PMID: 6435654.

(Cross sectional study of antipyrine clearance in 122 patients with epilepsy, found dose dependent increase in clearance in those on phenytoin, phenobarbital and carbamazepine, but not on valproate).

Davion T, Capron-Chivrac D, Andrejak M, Capron JP. [Hepatitis due to antiepileptic agents] Gastroenterol Clin Biol 1985; 9: 117-26. French. PubMed PMID: 3920108.

(Review of 15 cases of carbamazepine hepatotoxicity in the literature; onset in 3-4 weeks in most cases, but occasionally longer; granulomatous hepatitis in 8 of 14 cases with biopsy, these cases being invariably benign; three reports of acute liver failure).

Larrey D, Hadengue A, Pessayre D, Choudat L, Degott C, Benhamou J-P. Carbamazepine-induced acute cholangitis. *Dig Dis Sci* 1987; 32: 554-7. PubMed PMID: 3568943.

(79 year old woman developed itching 4 weeks and fever and jaundice [no rash] 7 weeks after starting clonazepam and carbamazepine [bilirubin 6.6 mg/dL, ALT 91 U/L, Alk P 5x ULN, 54% eosinophils], liver biopsy showed cholestasis and "cholangitis", resolving within 3 months of stopping carbamazepine, clonazepam being restarted).

Reinikainen KJ, Keranen T, Halonen T, Komulainen H, Riekkinen PJ. Comparison of oxcarbazepine and carbamazepine: a double-blind study. *Epilepsy Research* 1987; 1: 284-9. PubMed PMID: 3504404.

(Among 18 patients on carbamazepine and 16 on oxcarbazepine, 2 developed transient ALT and AST elevations neither requiring dose adjustment).

Pellock JM. Carbamazepine side effects in children and adults. *Epilepsia* 1987; 28 Suppl 3: S64-70. PubMed PMID: 2961558.

(Analysis of side effects among 220 children on carbamazepine; skin rash in 5% and elevated liver tests in 6% but none "were of clinical significance." Reports to Ciba-Geigy from 1975-86 included 45 with hepatitis and [5-10%] of patients with liver enzyme elevations).

Shear NH, Spielberg SP. Anticonvulsant hypersensitivity syndrome: in vitro assessment of risk. *J Clin Invest* 1988; 82: 1826-32. PubMed PMID: 3198757.

(PBMC cytotoxicity in response to drug metabolites from 53 patients with hypersensitivity to anticonvulsants including 35/36 to phenytoin, 22/27 to phenobarbital, and 25/27 to carbamazepine; 51% had hepatitis).

Robbie MJ, Scurry JP, Stevenson P. Carbamazepine-induced severe systemic hypersensitivity reaction with eosinophilia. *Drug Intell Clin Pharm* 1988; 22: 783-4. PubMed PMID: 3229345.

(35 year old woman developed rash 3 weeks after starting carbamazepine, followed by fever and dyspnea with eosinophilia, respiratory and renal failure, responding to prednisone but then relapsing, developing jaundice late [bilirubin 8.8 mg/dL, AST 120 U/L, Alk P 2220 U/L], death from multiorgan failure 12 weeks later).

Aldenhövel HG. The influence of long-term anticonvulsant therapy with diphenylhydantoin and carbamazepine on serum gamma-glutamyltransferase, aspartate aminotransferase, alanine aminotransferase and alkaline phosphatase. *Eur Arch Psychiatry Neurol Sci* 1988; 237: 312-6. PubMed PMID: 2901959.

(Among 54 patients on phenytoin and 56 on carbamazepine, elevations in GGT [14-283 U/L] were present in 91% and 64%, ALT [5-81 U/L] in 28% and 9%, and Alk P [71-216 U/L] in 39% vs 14%, most elevations were modest; GGT elevations were dose related, but not the others).

Dam M, Ekberg R, Løyning Y, Waltimo O, Jakobsen K. A double-blind study comparing oxcarbazepine and carbamazepine in patients with newly diagnosed, previously untreated epilepsy. *Epilepsy Res* 1989; 3: 70-6. PubMed PMID: 2645120.

(Controlled trial of oxcarbazepine vs carbamazepine in 235 patients with epilepsy found similar therapeutic effect but lower rate of side effects with oxcarbazepine; liver tests fluctuated during therapy but only one patient [on carbamazepine] required drug discontinuation because of liver injury).

Durelli L, Massazza U, Cavallo R. Carbamazepine toxicity and poisoning. Incidence, clinical features and management. *Med Toxicol Adverse Drug Exp* 1989; 4: 95-107. PubMed PMID: 2654545.

(Review of pharmacology and toxicity of carbamazepine; symptoms of overdose are largely neurological).

Askmark H, Wiholm B. Epidemiology of adverse reactions to carbamazepine as seen in a spontaneous reporting system. *Acta Neurol Scand* 1990; 81: 131-40. PubMed PMID: 2327233.

- (Analysis of 505 reports of adverse reaction to carbamazepine during 92 million dose-days from 1965-1987 in Sweden; 71 were liver related [16/100,000 treatment years], 21 with isolated ALT elevation after 4-46 days, 18 with ALT and Alk P elevations [after 16-60 days], and 25 with jaundice after 6 days to 2 years).*
- Frey B, Schubiger G, Musy JP. Transient cholestatic hepatitis in a neonate associated with carbamazepine exposure during pregnancy and breast-feeding. *Eur J Pediatr* 1990; 150: 136-8. PubMed PMID: 2279511.
- (Persistent jaundice at 3 weeks in male infant being breastfed by mother on carbamazepine [direct/total bilirubin 2.4/13.0 mg/dL, ALT 31 U/L, Alk P 402 U/L], liver biopsy showed cholestatic hepatitis, with rapid recovery on stopping).*
- Merlob P, Mor N, Litwin A. Transient hepatic dysfunction in an infant of an epileptic mother treated with carbamazepine during pregnancy and breastfeeding. *Ann Pharmacother* 1992; 26: 1563-5. PubMed PMID: 1362364.
- (Newborn girl being breast fed by a mother taking carbamazepine had persisting jaundice in first 2 weeks of life [direct/total bilirubin 1.4/3.4 mg/dL, ALT 32 U/L, Alk P 293 U/L on day 5], resolving rapidly with stopping breastfeeding).*
- Forbes GM, Jeffrey GP, Shilkin KB, Reed WD. Carbamazepine hepatotoxicity: another cause of the vanishing bile duct syndrome. *Gastroenterology* 1992; 102: 1385-8. PubMed PMID: 1551543.
- (59 year old man developed fever, rash and jaundice 2 months after starting carbamazepine [bilirubin 12.4 mg/dL, AST 99 U/L, Alk P 1030 U/L], evolving into chronic cholestasis and vanishing bile duct syndrome, which improved clinically, but liver tests were still abnormal 1 year later).*
- Friis ML, Kristensen O, Boas J, et al. Therapeutic experiences with 947 epileptic out-patients in oxcarbazepine treatment. *Acta Neurol Scand* 1993; 87: 224-7. PubMed PMID: 8475694.
- (Retrospective study of 947 patients treated with oxcarbazepine in 8 centers from 1981-90: adverse events in 33%, rash in 6%, elevations in laboratory results [ALT, AST, GGT or WBC] in <2%).*
- Wallace SJ. A comparative review of the adverse effects of anticonvulsants in children with epilepsy. *Drug Saf* 1996; 15: 378-93. PubMed PMID: 8968693.
- (Systematic review; ALT elevations occur in 4% of children on phenytoin, 6% on valproate, 1% on carbamazepine but none reported in children on tiagabine or gabapentin).*
- Nathan DL, Belsito DV. Carbamazepine-induced pseudolymphoma with CD-30 positive cells. *J Am Acad Dermatol* 1998; 38: 806-9. PubMed PMID: 9591791.
- (44 year old woman with a history of phenytoin sensitivity developed fever, lymphadenopathy, pneumonitis, and rash one month after starting carbamazepine [bilirubin not given, AST 282 U/L, Alk P 44 U/L] and atypical CD-30 T cells in blood, resolution in 3 weeks on stopping).*
- Schlienger RG, Shear NH. Antiepileptic drug hypersensitivity syndrome. *Epilepsia* 1998; 39 (Suppl 7): S3-7. PubMed PMID: 9798755.
- (Review of the clinical features of anticonvulsant hypersensitivity syndrome).*
- Hamer HM, Morris HH. Hypersensitivity syndrome to antiepileptic drugs: a review including new anticonvulsants. *Clevel Clin J Med* 1999; 66: 239-45. PubMed PMID: 10199060.
- (Clinical review of anticonvulsant hypersensitivity syndrome, which occurs in 1-5 per 10,000 users, higher risk in African Americans and affected siblings; liver involvement common, but most cases anicteric; other manifestations include facial edema, lymphadenopathy, bone marrow aplasia, pseudolymphoma, thyroiditis, interstitial nephritis).*

Knowles SR, Shapiro LE, Shear NH. Anticonvulsant hypersensitivity syndrome: incidence, prevention and management. *Drug Saf* 1999; 21: 489– 501. PubMed PMID: 10612272.

(Review of anticonvulsant hypersensitivity syndrome: triad of fever, rash and internal organ injury occurring 1-8 weeks after exposure to anticonvulsant; liver being most common internal organ involved. Occurs in 1:1000-1:10,000 initial exposures to phenytoin, carbamazepine, phenobarbital or lamotrigine, unrelated to dose, perhaps predisposed by valproate; liver injury arises 1-4 weeks after onset of rash and ranges in severity from asymptomatic ALT elevations to icteric hepatitis to acute liver failure. High mortality rate with jaundice; other organs include muscle, kidney, brain, heart and lung. Pseudolymphoma syndrome and serum sickness like syndrome are separate complications of anticonvulsants. Role of corticosteroids uncertain; cross reactivity among the agents should be assumed).

Hamer HM, Morris HH. Successful treatment with gabapentin in the presence of hypersensitivity syndrome to phenytoin and carbamazepine: a report of three cases. *Seizure* 1999; 8: 190-2. PubMed PMID: 10356381.

(3 patients developed rash, fever, lymphadenopathy and eosinophilia 4-6 weeks after starting either phenytoin or carbamazepine [bilirubin 0.5-1.8 mg/dL, ALT 866-1402 U/L, Alk P 69-364 U/L], resolving after stopping and not recurring during gabapentin therapy).

Descamps V, Valance A, Edlinger C, et al. Association of human herpesvirus 6 infection with drug reaction with eosinophilia and systemic symptoms. *Arch Dermatol* 2001; 137: 301-4. PubMed PMID: 11255328.

(Among 7 patients with DRESS syndrome, all had anti-HHV-6, 2 in rising titers, 4 with IgM, none had HHV-6 DNA; 5 cases due to carbamazepine, 1 sulfasalazine and 1 ibuprofen).

Sullivan JR, Shear NH. The drug hypersensitivity syndrome. What is the pathogenesis? *Arch Dermatol* 2001; 137: 357-64. PubMed PMID: 11255340.

(Review of clinical features, major causes and suspected pathogenesis of DRESS; major causes are aromatic anticonvulsants, abacavir, azathioprine, and sulfonamides).

Garcia M, Mhanna MJ, Chung-Park MJ, Davis PH, Srivastava MD. Efficacy of early immunosuppressive therapy in a child with carbamazepine-associated vanishing bile duct and Stevens-Johnson syndromes. *Dig Dis Sci* 2002; 47: 177-82. PubMed PMID: 11837721.

(4 year old developed necrotizing rash and fever 4 months after starting carbamazepine [bilirubin 4.0 mg/dL, ALT 673 U/L, Alk P 481 U/L, GGT 613 U/L], Stevens-Johnson syndrome; biopsy showing “early” vanishing bile duct syndrome, treated with corticosteroids with rapid response but slow decline in GGT and cholesterol at the time of 6 week follow up).

Frey B, Braegger CP, Ghelfi D. Neonatal cholestatic hepatitis from carbamazepine exposure during pregnancy and breast feeding. *Ann Pharmacother* 2002; 36: 644-7. PubMed PMID: 11918515.

(Newborn boy developed jaundice and mild elevations in GGT, Alk P and ALT 3 to 4 weeks after difficult birth to mother on carbamazepine who breastfed: two previous cases discussed).

Bosdure E, Cano A, Roquelaure B, Reynaud R, Boyer M, Viard L, Sarles J. [Oxcarbazepine and DRESS syndrome: a paediatric cause of acute liver failure]. *Arch Pediatr* 2004; 11: 1073-7. French. PubMed PMID: 15350998.

(11 year old girl developed rash, fever and eosinophilia 43 days after starting oxcarbazepine [bilirubin not given, ALT 25 times ULN, Alk P not given, factor V 15%], progressing to hepatic failure, but eventually improving spontaneously and resolving completely within 6 weeks).

Tohyama M, Hashimoto K, Yasukawa M, Kimura H, Horikawa T, Nakajima K, Urano Y, et al. Association of human herpesvirus 6 reactivation with the flaring and severity of drug-induced hypersensitivity syndrome. *Br J Dermatol* 2007; 157: 934-40. (PubMed PMID: 17854362.

Anti-HHV-6 testing of 100 patients with drug induced hypersensitivity syndrome [34% with hepatitis] found rise in IgG levels in 62 patients, largely in more severe cases; HHV-6 DNA detected in 18; drugs included carbamazepine, phenobarbital, phenytoin, allopurinol, sulfasalazine and mexiletine).

Ganeva M, Gancheva T, Lazarova R, et al. Carbamazepine-induced drug reaction with eosinophilia and systemic symptoms(DRESS) syndrome: report of four cases and brief review. *Int J Dermatol* 2008; 47: 853-60. (Review of carbamazepine induced hypersensitivity syndromes and 4 case reports; onset after 3-4 weeks of starting carbamazepine with rash, fever and eosinophilia, 2 with liver involvement and 1 with jaundice, all treated with corticosteroids and all resolved without recurrence, 3 taking valproate). PubMed PMID: 18717872.

Chalasani N, Fontana RJ, Bonkovsky HL, Watkins PB, Davern T, Serrano J, Yang H, Rochon J; Drug Induced Liver Injury Network (DILIN). Causes, clinical features, and outcomes from a prospective study of drug-induced liver injury in the United States. *Gastroenterology* 2008; 135: 1924-34. PubMed PMID: 18955056.

(Among 300 cases of drug induced liver disease in the US collected between 2004 and 2008, valproate accounted for 6, lamotrigine 5, phenytoin 5, gabapentin and topiramate 1 each; none due to oxcarbazepine).

Björnsson E. Hepatotoxicity associated with antiepileptic drugs. *Acta Neurol Scand* 2008; 118: 281-90. PubMed PMID: 18341684.

(Review of all anticonvulsants including 60 cases of carbamazepine usually part of hypersensitivity syndrome, typically mixed enzyme pattern, 27% with eosinophilia, mean onset at 5 weeks, 17% mortality more common in children, with hepatocellular pattern of enzymes and with longer latency to onset; mentions oxcarbazepine has been linked to a few cases reports showing mild-to-moderate liver test elevations).

Franzoni E, Gentile V, Pellicciari A, Garone C, Iero L, Gualandi S, Cordelli DM, et al. Prospective study on long-term treatment with oxcarbazepine in pediatric epilepsy. *J Neurol* 2009; 256: 1527-32. PubMed PMID: 19597919.

(Among 36 children with epilepsy treated with oxcarbazepine for up to 3 years, "no hepatic dysfunctions were reported").

Buggy Y, Layton D, Fogg C, Shakir SA. Safety profile of oxcarbazepine: results from a prescription-event monitoring study. *Epilepsia* 2010; 51: 818-29. (PubMed PMID: 20132298.

Results of mail survey of 2243 patients given a prescription for oxcarbazepine by physicians in England between 2000 and 2003, mostly for seizures but also trigeminal neuralgia and neuropathic pain; 40% as monotherapy, most common side effects were sedation, nausea, malaise and dizziness; no mention of liver injury or ALT elevations).

Hsu HF, Huang SY. Severe hepatitis associated with administration of oxcarbazepine. *Pediatr Int* 2010; 52: 677-8. PubMed PMID: 20958883.

(8 year old girl with partial seizures developed malaise, fever and pharyngitis without rash 12 days after starting oxcarbazepine [bilirubin 0.6 mg/dL, ALT 1258 U/L, ALk P 128 U/L], resolving rapidly upon stopping and then tolerating levetiracetam).

Drugs for epilepsy. *Treat Guidel Med Lett* 2013; 11: 9-18. PubMed PMID: 23348233.

(Concise review of drugs of choice for epilepsy; oxcarbazepine alone or in combination is useful for treatment of partial seizures; adverse events include somnolence, dizziness, diplopia, ataxia, nausea and vomiting; liver injury is not mentioned).