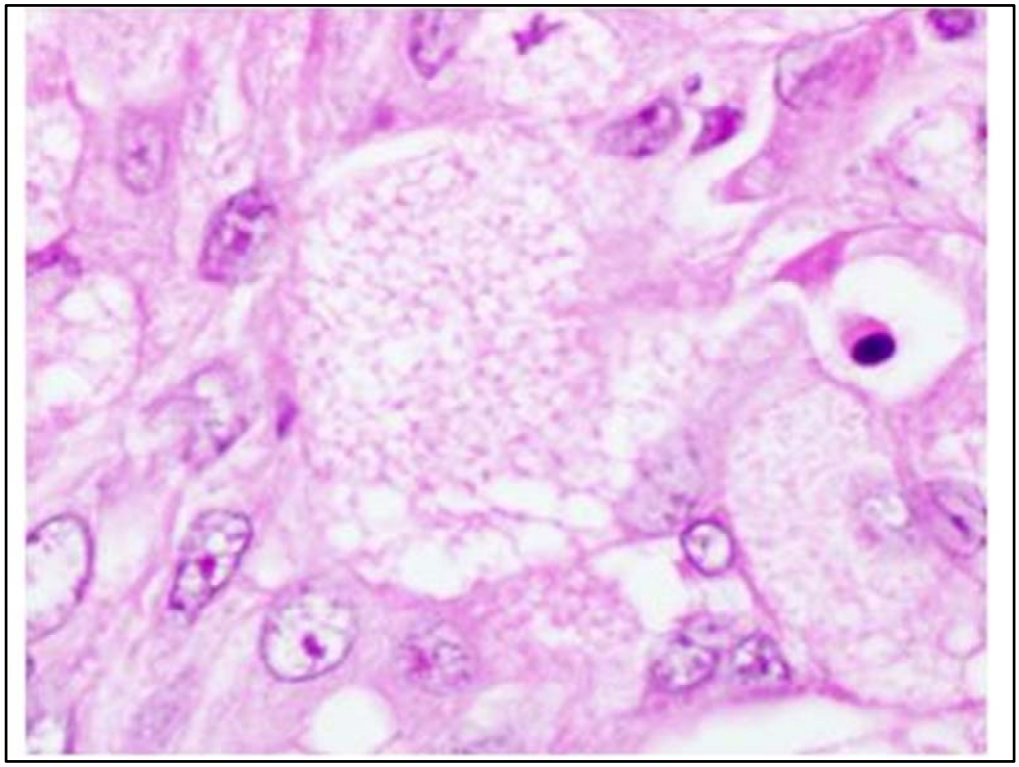

Microvesicular steatosis due to fialuridine toxicity: A digitally enlarged micrograph demonstrating the fine vacuolation seen in microvesicular steatosis.