



Irinotecan

Updated: April 27, 2018.

OVERVIEW

Introduction

Irinotecan and topotecan are semisynthetic derivatives of the plant alkaloid camptothecin and are used as antineoplastic agents in the therapy of colorectal, ovarian and non-small cell lung cancer. Both irinotecan and topotecan are associated with an appreciable rate of serum enzyme elevations during therapy, and irinotecan has been implicated in causing steatohepatitis when given as cyclic anticancer therapy.

Background

Irinotecan (eye" ri noe tee' kan) and topotecan (toe" poe tee' kan) are semisynthetic derivatives of camptothecin, a plant alkaloid derived from the Chinese tree, *Camptotheca acuminata*. Both drugs appear to act by blocking DNA topoisomerase I, which is responsible for relaxation of supercoiled double stranded DNA so that replication can proceed. Topoisomerase I activity is particularly increased in cancer cells. Irinotecan and topotecan have antineoplastic activity against colorectal, non-small cell lung and breast cancer in vivo and in vitro. Irinotecan and topotecan were both approved for use in the United States in 1996 and continue to be used in oncology practice. Current formal indications for irinotecan are advanced colorectal cancer alone or in combination with other antineoplastic agents (usually fluorouracil). Irinotecan is available generically and under the brand name Camptosar in 2, 5 and 15 mL vials of 20 mg/mL. The typical dose varies is based upon body weight and is adjusted by whether it is used alone or in combination with other anticancer agents. The approved indications for topotecan include advanced or metastatic ovarian and cervical cancer and small cell lung cancer (after failure of first line chemotherapy). Topotecan is available in solution in 4 mg single dose vials generically and under the trade name Hycamtin. The typical dose varies by indication and body weight. Side effects of irinotecan and topotecan are similar and include bone marrow suppression, nausea, vomiting, abdominal pain, stomatitis, diarrhea, fatigue, hair loss and peripheral neuropathy. Infusions of irinotecan can be associated with severe diarrhea which is typically delayed and is treated with loperamide. Irinotecan also can cause an acute cholinergic syndrome marked by hypotension, diarrhea, sweating, lacrimation and fatigue, which is typically treated with atropine.

Hepatotoxicity

Chemotherapy with irinotecan and topotecan in combination with other agents is associated with serum enzyme elevations in up to 15% of patients depending upon the dose, other agents used, the frequency of monitoring and degree of elevation that is reported. The ALT elevations are usually asymptomatic and transient and may resolve without dose modification. Marked elevations occur in 1% to 4% of patients, but rarely require dose modification. Genetic variants in hepatic transporters and metabolic enzymes have been associated with

predisposition to irinotecan toxicity, including OATP 1B1 (SLC01B1), UGT1A1 and CYP 3A4. However, the major toxicities of irinotecan are hematologic and diarrhea, and liver test elevations are rare causes of drug interruption or dose modification.

Irinotecan has been linked to chemotherapy induced steatosis and steatohepatitis. This can be shown by imaging or histologically, but is usually associated with minimal symptoms or laboratory test abnormalities. Cyclic therapy with irinotecan is often used to treat hepatic metastases from colorectal cancer in preparation for hepatic resection, and both steatosis and steatohepatitis have been found to be frequent in the nontumorous part of the liver at the time of resection. These abnormalities are often associated with mild to moderate elevations in serum aminotransferase and alkaline phosphatase levels, but are rarely symptomatic or accompanied by jaundice. Intriguingly, the steatosis and steatohepatitis associated with chemotherapy tends to persist long term, as opposed to sinusoidal obstruction syndrome and nodular regenerative hyperplasia which tend to improve or resolve over time. Steatohepatitis may be associated with an increased rate of complications after hepatic resection probably as a result of inhibition of hepatic regeneration. On the other hand, steatohepatitis following adjuvant irinotecan therapy has not been clearly associated with a decrease in survival or an increased rate of hepatic failure after major hepatic resection. In addition, irinotecan has not been clearly associated with instances of sinusoidal obstruction syndrome or nodular regenerative hyperplasia, the common complications of oxaliplatin therapy, which is a frequently used alternative to irinotecan in managing advanced and metastatic colorectal cancer.

Likelihood score irinotecan: B (likely cause of clinically apparent liver injury).

Topotecan is a less frequently used topoisomerase inhibitor and has been associated with serum enzyme elevations in up to 50% of patients, but these have been transient, mild and not associated with jaundice or symptoms. Since licensure and more wide scale use, topotecan has not been associated with instances of clinically apparent liver injury.

Likelihood score topotecan: E* (unproven but suspected cause of clinically apparent liver injury).

Mechanism of Injury

Irinotecan is extensively metabolized in the liver and undergoes modification by CYP 3A and uridine diphosphate-glucuronosyltransferase (UGT1A1), the enzyme responsible for conjugation of bilirubin and is partially deficient in persons with Gilbert syndrome. As a consequence, adverse events to irinotecan therapy (such as neutropenia and diarrhea) are more common in patients with hyperbilirubinemia and Gilbert syndrome. The cause of steatosis and steatohepatitis from irinotecan therapy is not known, but may relate to generation of toxic intermediates of its metabolism.

Outcome and Management

The hepatic injury caused by irinotecan and topotecan is usually mild and asymptomatic, and neither agent has been linked to cases of prolonged cholestasis or vanishing bile duct syndrome. The results of rechallenge after cases of clinically apparent insult have not been reported.

Drug Class: [Antineoplastic Agents](#)

Other Drugs in the Subclass, [Topoisomerase Inhibitors](#): [Etoposide](#), [Teniposide](#)

PRODUCT INFORMATION

REPRESENTATIVE TRADE NAMES

Box continues on next page...

Box continued from previous page.

Irinotecan – Generic, Camptosar®

Topotecan – Generic, Hycamtin®

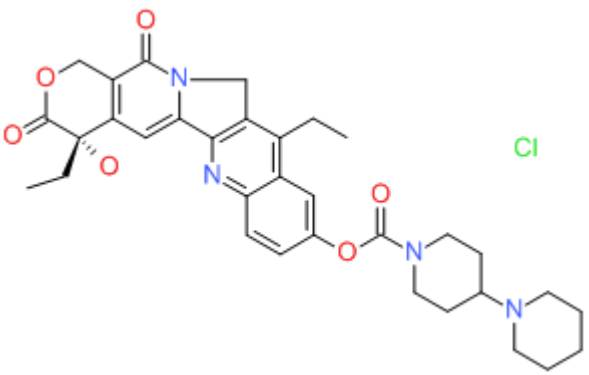
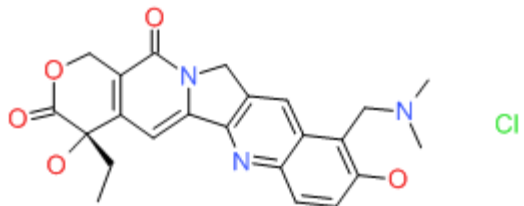
DRUG CLASS

Antineoplastic Agents

COMPLETE LABELING

Product labeling at DailyMed, National Library of Medicine, NIH

CHEMICAL FORMULAS AND STRUCTURES

DRUG	CAS REGISTRY NO.	MOLECULAR FORMULA	STRUCTURE
Irinotecan	100286-90-6	C ₃₃ -H ₃₈ -N ₄ -O ₆ .Cl-H	
Topotecan	119413-54-6	C ₂₃ -H ₂₃ -N ₃ -O ₅ .Cl-H	

ANNOTATED BIBLIOGRAPHY

References updated: 27 April 2018

Zimmerman HJ. Hepatotoxic effects of oncotherapeutic and immunosuppressive agents. In, Zimmerman HJ. Hepatotoxicity: the adverse effects of drugs and other chemicals on the liver. 2nd ed. Philadelphia: Lippincott, 1999, pp. 673-708.

(Expert review of hepatotoxicity of antineoplastic agents published in 1999; does not discuss the topoisomerase I inhibitors, irinotecan or topotecan).

Chabner BA, Bertino J, Cleary J, Ortiz T, Lane A, Supko JG, Ryan DP. Camptothecin analogues. Cytotoxic agents. In, Brunton LL, Chabner BA, Knollman BC, eds. Goodman & Gilman's the pharmacological basis of therapeutics. 12th ed. New York: McGraw-Hill, 2011, pp. 1710-2.

(Textbook of pharmacology and therapeutics; mentions that irinotecan and topotecan are the only camptothecin analogues approved for clinical use and have activity in colorectal, ovarian and small cell lung cancer, and both can cause elevations in serum aminotransferase levels).

Bleiberg H, Cvitkovic E. Characterisation and clinical management of CPT-11 (irinotecan)-induced adverse events: the European perspective. *Eur J Cancer* 1996; 32A Suppl 3: S18-23. PubMed PMID: 8943661.

(In early studies, the major adverse events of irinotecan therapy in colorectal cancer were neutropenia [80%], nausea [78%], asthenia [81%], alopecia [81%], cholinergic syndrome [85%], and diarrhea [87%], which was usually delayed and sometimes required hospitalization; no discussion of ALT elevations or hepatotoxicity).

Merrouche Y, Extra JM, Abigeres D, Bugat R, Catimel G, Suc E, Marty M, et al. High dose-intensity of irinotecan administered every 3 weeks in advanced cancer patients: a feasibility study. *J Clin Oncol* 1997; 15: 1080-6. PubMed PMID: 9060548.

(Among 35 patients with advanced cancer, high doses of irinotecan were poorly tolerated, adverse events including severe neutropenia and diarrhea, "a moderate and reversible increase in hepatic transaminases was observed in three cases").

Rougier P, Bugat R, Douillard JY, Culine S, Suc E, Brunet P, Becouarn Y, et al. Phase II study of irinotecan in the treatment of advanced colorectal cancer in chemotherapy-naïve patients and patients pretreated with fluorouracil-based chemotherapy. *J Clin Oncol* 1997; 15: 251-60. PubMed PMID: 8996150.

(Among 213 French patients with advanced colorectal cancer treated with 1195 cycles of irinotecan [every 3 weeks], major side effects were neutropenia [47%], anemia [9%], thrombocytopenia [4%], diarrhea [37%] and cholinergic syndrome; ALT elevations occurred largely in patients with hepatic metastases).

Ardizzoni A, Hansen H, Dombernowsky P, Gamucci T, Kaplan S, Postmus P, Giaccone G, et al. Topotecan, a new active drug in the second-line treatment of small-cell lung cancer: a phase II study in patients with refractory and sensitive disease. The European Organization for Research and Treatment of Cancer Early Clinical Studies Group and New Drug Development Office, and the Lung Cancer Cooperative Group. *J Clin Oncol* 1997; 15: 2090-6. PubMed PMID: 9164222.

(Among 101 patients with small cell lung cancer treated with 403 courses of chemotherapy with topotecan, toxicity was mainly hematologic, liver test abnormalities occurred during 17% of courses, but were usually mild-to-moderate and transient with no instance of clinically apparent liver injury).

Bookman MA, Malmström H, Bolis G, Gordon A, Lissoni A, Krebs JB, Fields SZ. Topotecan for the treatment of advanced epithelial ovarian cancer: an open-label phase II study in patients treated after prior chemotherapy that contained cisplatin or carboplatin and paclitaxel. *J Clin Oncol* 1998; 16: 3345-52. PubMed PMID: 9779711.

(Among 139 women with refractory advanced ovarian cancer treated with topotecan, severe neutropenia occurred in 82%, but nonhematologic adverse events were mild; no mention of ALT elevations or hepatotoxicity).

Ohtsu T, Sasaki Y, Igarashi T, Murayama T, Kobayashi Y, Tobinai K. Unexpected hepatotoxicities in patients with non-Hodgkin's lymphoma treated with irinotecan(CPT-11) and etoposide. *Jpn J Clin Oncol* 1998; 28: 502-6. PubMed PMID: 9769785.

(All 3 patients with refractory lymphoma treated with irinotecan and etoposide [topoisomerase I and II inhibitors] developed ALT elevations >2.5 ULN and one developed jaundice, but all recovered).

Cersosimo RJ. Irinotecan: a new antineoplastic agent for the management of colorectal cancer. *Ann Pharmacother* 1998; 32: 1324-33. PubMed PMID: 9876815.

(Review of structure, pharmacology, efficacy and safety of irinotecan; the major dose limiting side effects are myelosuppression and diarrhea, and transient elevations in liver tests may occur [AST in 10.5% and Alk P in 13.2%]).

Levine EG, Cirrincione CT, Szatrowski TP, Canellos G, Norton L, Henderson IC. Phase II trial of topotecan in advanced breast cancer: a Cancer and Leukemia Group B study. *Am J Clin Oncol.* 1999; 22: 218-22. PubMed PMID: 10362325.

(Among 40 women with advanced, refractory breast cancer treated with topotecan in 21 day cycles, most toxicities were hematologic; no mention of ALT elevations or hepatotoxicity).

von Pawel J, Schiller JH, Shepherd FA, Fields SZ, Kleisbauer JP, Chrysson NG, Stewart DJ, et al. Topotecan versus cyclophosphamide, doxorubicin, and vincristine for the treatment of recurrent small-cell lung cancer. *J Clin Oncol* 1999; 17: 658-67. PubMed PMID: 10080612.

(Among 107 patients with refractory, recurrent small cell lung cancer treated with topotecan, severe neutropenia occurred in 38%, but nonhematologic toxicities were mild-to-moderate; no mention of ALT elevations or hepatotoxicity).

Tsutani H, Inai K, Kishi S, Morinaga K, Naiki H, Ueda T. Hepatic tumor rupture following effectual treatment with irinotecan in a patient with highly refractory malignant lymphoma. *Int J Hematol* 1999; 70: 178-80. PubMed PMID: 10561911.

(60 year old man with advanced, refractory non-Hodgkin lymphoma involving the liver had marked response to irinotecan therapy, with the hepatic mass shrinking from 8 x 6 cm to 4.5 x 3 cm, but subsequent hepatic rupture, autopsy showing necrotic nodular masses with fissures on the surface).

DeVore RF, Johnson DH, Crawford J, Garst J, Dimery IW, Eckardt J, Eckhardt SG, et al. Phase II study of irinotecan plus cisplatin in patients with advanced non-small-cell lung cancer. *J Clin Oncol* 1999; 17: 2710-20. PubMed PMID: 10561345.

(Among 52 patients with advanced non-small cell lung cancer treated with irinotecan and cisplatin side effects were common [100% had nausea and dyspnea], but hepatotoxicity and ALT elevations were not mentioned).

Mori K, Machida S, Yoshida T, Yoshida M, Kano Y, Tominaga K. A phase II study of irinotecan and infusional cisplatin with recombinant human granulocyte colony-stimulating factor support for advanced non-small-cell lung cancer. *Cancer Chemother Pharmacol* 1999; 43: 467-70. PubMed PMID: 10321506.

(Among 41 patients with advanced non-small cell lung cancer on cyclic irinotecan and cisplatin, transient, mild-to-moderate ALT or AST elevations occurred in 10 [24%]).

Van Cutsem E, Cunningham D, Ten Bokkel Huinink WW, Punt CJ, Alexopoulos CG, Dirix L, Symann M, et al. Clinical activity and benefit of irinotecan(CPT-11) in patients with colorectal cancer truly resistant to 5-fluorouracil(5-FU). *Eur J Cancer* 1999; 35: 54-9. PubMed PMID: 10211088.

(Among 107 patients with advanced colorectal cancer treated with irinotecan, side effects included alopecia [91%], nausea [88%], diarrhea [88%] and cholinergic syndrome [82%]; no mention of ALT elevations or hepatotoxicity).

Ong SY, Clarke SJ, Bishop J, Dodds HM, Rivory LP. Toxicity of irinotecan(CPT-11) and hepato-renal dysfunction. *Anticancer Drugs* 2001; 12: 619-25. PubMed PMID: 11487719.

(55 year old man with metastatic colorectal cancer developed severe neutropenia and diarrhea after irinotecan therapy and developed rise in bilirubin [0.7 to 4.6 mg/dL] and Alk P [~200 to 1150 U/L] and aminotransferase levels [above 5 times ULN], with slow ultimate recovery).

- Mugishima H, Matsunaga T, Yagi K, Asami K, Mimaya J, Suita S, Kishimoto T, et al. Phase I study of irinotecan in pediatric patients with malignant solid tumors. *J Pediatr Hematol Oncol* 2002; 24: 94-100. PubMed PMID: 11990713.
- (Among 28 children with refractory solid tumors treated with irinotecan, transient, mild-to-moderate liver tests abnormalities arose in 4 [14%]).*
- Rubbia-Brandt L, Audard V, Sartoretti P, Roth AD, Brezault C, Le Charpentier M, Dousset B, et al. Severe hepatic sinusoidal obstruction associated with oxaliplatin-based chemotherapy in patients with metastatic colorectal cancer. *Ann Oncol* 2004; 15: 460-6. PubMed PMID: 14998849.
- (Among 153 patients undergoing hepatic resection for colon cancer, centrolobular congestion and necrosis were found in nontumor liver tissue in 51% of those who received neoadjuvant chemotherapy, but in none undergoing surgery alone; oxiplatin as the most frequently implicated agent; follow up biopsies often showed fibrosis).*
- Fernandez FG, Ritter J, Goodwin JW, Linehan DC, Hawkins WG, Strasberg SM. Effect of steatohepatitis associated with irinotecan or oxaliplatin pretreatment on resectability of hepatic colorectal metastases. *J Am Coll Surg* 2005; 200: 845-53. PubMed PMID: 15922194.
- (Among patients undergoing hepatic resections for colorectal cancer metastases, steatohepatitis and liver injury were more common among the 14 who received oxaliplatin and/or irinotecan than 10 who received 5-FU alone or 13 given no chemotherapy).*
- Vauthey JN, Pawlik TM, Ribero D, Wu TT, Zorzi D, Hoff PM, Xiong HQ, et al. Chemotherapy regimen predicts steatohepatitis and an increase in 90-day mortality after surgery for hepatic colorectal metastases. *J Clin Oncol* 2006; 24: 2065-72. PubMed PMID: 16648507.
- (Among 406 patients undergoing hepatic resection for colorectal metastases, preoperative chemotherapy with oxaliplatin was associated with sinusoidal dilatation [19% vs 2%], whereas irinotecan was associated with steatohepatitis [20% vs 4.4%], which was associated with higher 90 day mortality rates).*
- Karoui M, Penna C, Amin-Hashem M, Mitry E, Benoist S, Franc B, Rougier P, et al. Influence of preoperative chemotherapy on the risk of major hepatectomy for colorectal liver metastases. *Ann Surg* 2006; 243: 1-7. PubMed PMID: 16371728.
- (Retrospective analysis of 67 patients undergoing hepatic resection of colorectal liver metastasis, found preoperative chemotherapy was associated with higher rates of complications [38% vs 14%] and hepatic failure [11% vs 0%] compared to no chemotherapy, despite no difference in degree of elevation of liver tests during first 10 postoperative days).*
- Takane H, Miyata M, Burioka N, Kurai J, Fukuoka Y, Suyama H, Shigeoka Y, Otsubo K, Ieiri I, Shimizu E. Severe toxicities after irinotecan-based chemotherapy in a patient with lung cancer: a homozygote for the SLCO1B1*15 allele. *Ther Drug Monit* 2007; 29: 666-8. PubMed PMID: 17898662.
- (61 year old man with advanced non-small cell lung cancer with a genetic variant of organic anion transporter polypeptide 1B1(OAT) had increased serum levels of the first metabolite of irinotecan [SN-38] and experienced severe toxicity to irinotecan therapy).*
- Pawlik TM, Olin K, Gleisner AL, Torbenson M, Schulick R, Choti MA. Preoperative chemotherapy for colorectal liver metastases: impact on hepatic histology and postoperative outcome. *J Gastrointest Surg* 2007; 11: 860-8. PubMed PMID: 17492335.
- (Among 212 patients with metastatic colorectal cancer undergoing resection, 55 had received irinotecan of whom 15 [27%] had marked steatosis and 2 [4%] steatohepatitis, compared to 59 patients who did not undergo chemotherapy of whom 2 [3%] had marked steatosis and none steatohepatitis).*

Zorzi D, Laurent A, Pawlik TM, Lauwers GY, Vauthey J-N, Abdalla EK. Chemotherapy-associated hepatotoxicity and surgery for colorectal liver metastases. *Brit J Surg* 2007; 94: 274-86. PubMed PMID: 17315288.

(Systematic review of liver toxicity occurring after preoperative systemic chemotherapy for colorectal liver metastases, focuses upon steatosis caused by irinotecan and many other agents, sinusoidal obstruction syndrome from oxiplatin, and sclerosing cholangitis from floxuridine).

Eckardt JR, von Pawel J, Pujol JL, Papai Z, Quoix E, Ardizzoni A, Poulin R, et al. Phase III study of oral compared with intravenous topotecan as second-line therapy in small-cell lung cancer. *J Clin Oncol* 2007; 25: 2086-92. PubMed PMID: 17513814.

(Among 309 patients with advanced small cell lung cancer treated with either oral or intravenous topotecan, nonhematologic toxicities included diarrhea, fatigue, dyspnea, anorexia and nausea; no mention of ALT elevations or hepatotoxicity).

Seifart U, Fink T, Schade-Brittinger C, Hans K, Mueller C, Koschel G, Schroeder H, et al. Randomised phase II study comparing topotecan/carboplatin administration for 5 versus 3 days in the treatment of extensive-stage small-cell lung cancer. *Ann Oncol* 2007; 18: 104-9. PubMed PMID: 17071939.

(Among 100 patients with metastatic small cell lung cancer treated with topotecan and carboplatin in up to six cycles of either 3 or 5 days, hematologic toxicity [largely neutropenia] was the main side effect; no mention of ALT levels or hepatotoxicity).

Chalasan N, Fontana RJ, Bonkovsky HL, Watkins PB, Davern T, Serrano J, Yang H, Rochon J. Drug Induced Liver Injury Network (DILIN). Causes, clinical features, and outcomes from a prospective study of drug-induced liver injury in the United States. *Gastroenterology* 2008; 135: 1924-34. PubMed PMID: 18955056.

(Among 300 cases of drug induced liver disease in the US collected between 2004 and 2008, several cases were attributed to antineoplastic agents [such as mercaptopurine, cyclophosphamide, docetaxel, temozolomide, bortezomib and imatinib], but none to irinotecan or topotecan).

Kudo D, Tsutsumi S, Akasaka H, Jin H, Ohashi T, Muroya T, Hasebe T, et al. [Predictive factors for histopathological liver injury in the patients who received preoperative systemic chemotherapy for colorectal liver metastases]. *Gan To Kagaku Ryoho* 2009; 36: 2025-7. Japanese. PubMed PMID: 20037312.

(Abstract only; among 47 patients undergoing hepatic resections for metastatic colorectal cancer, sinusoidal dilation but not steatohepatitis was more common among those who received preoperative oxaliplatin chemotherapy).

Cleary JM, Tanabe KT, Lauwers GY, Zhu AX. Hepatic toxicities associated with the use of preoperative systemic therapy in patients with metastatic colorectal adenocarcinoma to the liver. *Oncologist* 2009; 14: 1095-105. PubMed PMID: 19880627.

(Review of hepatic complications of chemotherapy for colorectal cancer; steatohepatitis has been associated with irinotecan therapy and BMI and linked to poor outcomes).

Choti MA. Chemotherapy-associated hepatotoxicity: do we need to be concerned? *Ann Surg Oncol*. 2009 Sep; 16: 2391-4. PubMed PMID: 19554374.

(Review on chemotherapy associated liver injury and its impact on surgical outcome after hepatic resection for colorectal cancer; irinotecan and 5-FU have been linked to steatosis and steatohepatitis).

Ramachandran R, Kakar S. Histological patterns in drug-induced liver disease. *J Clin Pathol* 2009; 62: 481-92. PubMed PMID: 19474352.

(Review of histology of drug induced liver injury discusses the "chemotherapy induced steatohepatitis" that is seen most frequently after irinotecan therapy).

Masi G, Loupakis F, Pollina L, Vasile E, Cupini S, Ricci S, Brunetti IM, et al. Long-term outcome of initially unresectable metastatic colorectal cancer patients treated with 5-fluorouracil/ leucovorin, oxaliplatin, and irinotecan (FOLFOXIRI) followed by radical surgery of metastases. *Ann Surg* 2009; 249: 420-5. PubMed PMID: 19247029.

(Among 196 patients with metastatic colorectal cancer who received chemotherapy, 37 were ultimately eligible for hepatic resection of the metastasis among whom all had sinusoidal dilation and 76% steatosis, which was severe in only 5% and associated with steatohepatitis in only 1).

Khan AZ, Morris-Stiff G, Makuuchi M. Patterns of chemotherapy-induced hepatic injury and their implications for patients undergoing liver resection for colorectal liver metastases. *J Hepatobiliary Pancreat Surg* 2009; 16: 137-44. PubMed PMID: 19093069.

(Review of liver injury from neoadjuvant therapy of colon cancer metastases and its clinical implications; irinotecan has been linked to steatosis and steatohepatitis, which may affect outcome of subsequent surgical resection of metastases).

Reuben A, Koch DG, Lee WM; Acute Liver Failure Study Group. Drug-induced acute liver failure: results of a U.S. multicenter, prospective study. *Hepatology* 2010; 52: 2065-76. PubMed PMID: 20949552.

(Review of the role and liver toxicity of chemotherapy for colorectal metastases; oxaliplatin is associated with sinusoidal injury and irinotecan with chemotherapy induced steatohepatitis [CASH]).

Chaudhury P, Hassanain M, Bouganim N, Salman A, Kavan P, Metrakos P. Perioperative chemotherapy with bevacizumab and liver resection for colorectal cancer liver metastasis. *HPB (Oxford)* 2010; 12: 37-42. PubMed PMID: 20495643.

(Among 35 patients with metastatic colorectal cancer who received bevacizumab before hepatic resection of liver metastases, 9 also received irinotecan but only 4 developed steatohepatitis and 2 jaundice postoperatively, but relationship of these events to irinotecan was not provided).

Takamoto T, Hashimoto T, Sano K, Maruyama Y, Inoue K, Ogata S, Takemura T, et al. Recovery of liver function after the cessation of preoperative chemotherapy for colorectal liver metastasis. *Ann Surg Oncol* 2010; 17: 2747-55. PubMed PMID: 20425145.

(Indocyanine green [ICG] testing of 55 patients receiving chemotherapy before hepatic resection for colorectal cancer metastases showed improvements in ISG clearance within 4 weeks of stopping therapy).

Ryan P, Nanji S, Pollett A, Moore M, Moulton CA, Gallinger S, Guindi M. Chemotherapy-induced liver injury in metastatic colorectal cancer: semiquantitative histologic analysis of 334 resected liver specimens shows that vascular injury but not steatohepatitis is associated with preoperative chemotherapy. *Am J Surg Pathol* 2010; 34: 784-91. PubMed PMID: 20421779.

(Among 334 patients undergoing hepatic resection for colorectal cancer metastases, marked hepatic steatosis was uncommon [9%] and correlated with BMI rather than chemotherapy, while sinusoidal lesions were present in 35% of cases and correlated with oxaliplatin use; neither correlated with immediate operative outcome).

Makowiec F, Möhrle S, Neeff H, Drognitz O, Illerhaus G, Opitz OG, Hopt UT, zur Hausen A. Chemotherapy, liver injury, and postoperative complications in colorectal liver metastases. *J Gastrointest Surg* 2011; 15: 153-64. PubMed PMID: 21061183.

(Among 102 patients undergoing hepatic resections for colorectal cancer metastases, steatosis was most common in those who had preoperative chemotherapy regardless of regimen [46% vs 18%], but BMI was a stronger risk factor and steatosis did not correlate with poor outcome).

Pilgrim CH, Thomson BN, Banting S, Phillips WA, Michael M. The developing clinical problem of chemotherapy-induced hepatic injury. *ANZ J Surg* 2012; 82: 23-9. PubMed PMID: 22507491.

(Review of types of liver injury from chemotherapy; oxaliplatin is associated with vascular and sinusoidal injury, whereas irinotecan is linked to steatohepatitis).

Narita M, Oussoultzoglou E, Chenard MP, Fuchshuber P, Rather M, Rosso E, Addeo P, et al. Liver injury due to chemotherapy-induced sinusoidal obstruction syndrome is associated with sinusoidal capillarization. *Ann Surg Oncol* 2012; 19: 2230-7. PubMed PMID: 22402811.

(Among 98 patients with colorectal cancer undergoing hepatic resection for metastases, 39 [36 of whom had received oxaliplatin] had changes of sinusoidal obstruction syndrome, and degree of changes correlated with isocyanine green [ICG] retention and overexpression of CD34, indicating capillarization of hepatic sinusoids).

Robinson SM, Wilson CH, Burt AD, Manas DM, White SA. Chemotherapy-associated liver injury in patients with colorectal liver metastases: a systematic review and meta-analysis. *Ann Surg Oncol* 2012; 19: 4287-99. PubMed PMID: 22766981.

(Histologic evaluation in 506 patients undergoing hepatic resection for colorectal cancer, showed that steatohepatitis was associated with irinotecan regimens, higher BMI and diabetes, whereas sinusoidal dilatation was not associated with chemotherapy; neither chemotherapy nor liver histology correlated with complications or deaths).

Lu QY, Zhao AL, Deng W, Li ZW, Shen L. Hepatic histopathology and postoperative outcome after preoperative chemotherapy for Chinese patients with colorectal liver metastases. *World J Gastrointest Surg* 2013; 5: 30-6. PubMed PMID: 23556058.

(Among 106 patients undergoing hepatic resections of colorectal cancer metastases after chemotherapy, 5 of 9 [56%] who received irinotecan had liver toxicity, including steatosis in 2 and steatohepatitis in 3).

Oshita F, Sugiura M, Murakami S, Kondo T, Saito H, Yamada K. Phase II study of nedaplatin and irinotecan in patients with extensive small-cell lung cancer. *Cancer Chemother Pharmacol* 2013; 71: 345-50. PubMed PMID: 23124649.

(Among 25 patients with small cell lung cancer treated with 4 cycles of nedaplatin and irinotecan, ALT elevations occurred in 10 [40%], but were transient and less than 5 times ULN in all).

Wolf PS, Park JO, Bao F, Allen PJ, DeMatteo RP, Fong Y, Jarnagin WR, et al. Preoperative chemotherapy and the risk of hepatotoxicity and morbidity after liver resection for metastatic colorectal cancer: a single institution experience. *J Am Coll Surg* 2013; 216: 41-9. PubMed PMID: 23041049.

(Among 384 patients undergoing liver resection for colorectal cancer metastases who had liver histology assessment, 35% had steatosis and 4% steatohepatitis, both of which were associated with higher BMI, diabetes and irinotecan chemotherapy, but these histologic features were not associated with major complications or death and no deaths were liver related).

von Pawel J, Jotte R, Spigel DR, O'Brien ME, Socinski MA, Mezger J, Steins M, et al. Randomized phase III trial of amrubicin versus topotecan as second-line treatment for patients with small-cell lung cancer. *J Clin Oncol* 2014; 32: 4012-9. PubMed PMID: 25385727.

(Among 637 patients with small-cell lung carcinoma treated with amrubicin or topotecan, overall survival was similar [7.5 vs 7.8 months] while hematologic adverse events were more common with topotecan, non-hematologic events rates were similar; no mention of ALT elevations or hepatotoxicity).

Enomoto Y, Inui N, Imokawa S, Karayama M, Hasegawa H, Ozawa Y, Matsui T, et al. Safety of topotecan monotherapy for relapsed small cell lung cancer patients with pre-existing interstitial lung disease. *Cancer Chemother Pharmacol* 2015; 76: 499-505. PubMed PMID: 26134440.

(Among 77 patients with relapsed small cell lung cancer treated with 1 to 7 courses of intravenous topotecan, adverse events were frequent including neutropenia [57%], febrile neutropenia [26%, one death] and exacerbation of preexisting interstitial lung disease [22%: 3 deaths]; no mention of hepatotoxicity).

Vincenzi B, Imperatori M, Picardi A, Vespasiani Gentilucci U, Gallo P, Fausti V, et al. Liver toxicity in colorectal cancer patients treated with first-line FOLFIRI-containing regimen: a single institution experience. *Expert Rev Anticancer Ther* 2015; 15: 971-6. PubMed PMID: 26112080.

(Among 156 patients with colorectal cancer treated with a "backbone" regimen of folinic acid, fluorouracil and irinotecan ["FOLFIRI"], most had serum enzyme elevations before starting [64%], and serum enzymes rose overall during the first 3 months of treatment [median peak level of ALT 168 U/L, Alk P 289 U/L, and bilirubin 1.2 mg/dL], while abnormal liver tests led to course delay in 16%, dose reduction in 8%, but discontinuation in only 2% and death in 0% of patients).

Chalasan N, Bonkovsky HL, Fontana R, Lee W, Stolz A, Talwalkar J, Reddy KR, et al.; United States Drug Induced Liver Injury Network. Features and outcomes of 899 patients with drug-induced liver injury: The DILIN Prospective Study. *Gastroenterology* 2015; 148: 1340-52.e7. PubMed PMID: 25754159.

(Among 899 cases of drug induced liver injury enrolled in a US prospective study between 2004 and 2013, 49 were attributed to antineoplastic agents [5.5%], but none were attributed to irinotecan to topotecan).

Goto K, Ohe Y, Shibata T, Seto T, Takahashi T, Nakagawa K, Tanaka H, Tet al; JCOG0605 investigators. Combined chemotherapy with cisplatin, etoposide, and irinotecan versus topotecan alone as second-line treatment for patients with sensitive relapsed small-cell lung cancer (JCOG0605): a multicentre, open-label, randomised phase 3 trial. *Lancet Oncol* 2016; 17: 1147-57. PubMed PMID: 27312053.

(Among 180 patients with relapsed small cell lung cancer treated with topotecan vs combination chemotherapy, overall survival was less with topotecan [12 vs 18 months], while adverse events were somewhat less including febrile neutropenia [7% vs 31%] and serious adverse events [4% vs 10%], while rates of ALT elevations were similar [37% vs 35% overall, above 5 times ULN 1% vs 2%], and there were 2 topotecan related deaths [both pulmonary]).

Vigano L, De Rosa G, Toso C, Andres A, Ferrero A, Roth A, Sperti E, Majno P, Rubbia-Brandt L. Reversibility of chemotherapy-related liver injury. *J Hepatol.* 2017; 67 (1): 84-91. PubMed PMID: 28284915.

(Among 524 liver resections done on 429 patients, rates of sinusoidal obstruction were less in patients whose resection was done more than 270 days after chemotherapy [19% vs 40%] as was nodular regenerative hyperplasia [8% vs 24%], but not steatosis [24% vs 36%] or steatohepatitis [10% vs 16%], but only NRH correlated with an increased liver failure rate [8% vs 3%]).

Duwe G, Knitter S, Pesthy S, Beierle AS, Bahra M, Schmelzle M, Schmuck RB, et al. Hepatotoxicity following systemic therapy for colorectal liver metastases and the impact of chemotherapy-associated liver injury on outcomes after curative liver resection. *Eur J Surg Oncol* 2017; 43: 1668-81. PubMed PMID: 28599872.

(Review of the hepatotoxicity of adjuvant therapy for metastatic colorectal cancer mentions that irinotecan is associated with steatosis and steatohepatitis which may impair hepatic regeneration, but have not been clearly linked to poor long term outcomes).

Poveda A, Del Campo JM, Ray-Coquard I, Alexandre J, Provansal M, Guerra Alía EM, Casado A, et al. Phase II randomized study of PM01183 versus topotecan in patients with platinum-resistant/refractory advanced ovarian cancer. *Ann Oncol* 2017; 28: 1280-7. PubMed PMID: 28368437.

(Among 59 patients with refractory advanced ovarian cancer treated with topotecan or an experimental anticancer agent, ALT elevations occurred in 51% of topotecan treated subjects, but most were mild and all were transient and less than 5 times ULN).