



Buprenorphine

Updated: May 20, 2014.

OVERVIEW

Introduction

Buprenorphine is an orally available, semisynthetic opioid analgesic, which is used as an analgesic and for management of opioid dependence. Therapy with buprenorphine has not been associated with serum enzyme elevations, and clinically apparent liver injury has been reported largely with overdose and abuse (intravenous administration of the sublingual formulation).

Background

Buprenorphine (bue" pre nor' feen) is a semisynthetic opioid that is 25 to 50 times more potent than morphine and has been used as an analgesic as well as therapy of opioid addiction. Buprenorphine is a partial μ -opioid receptor agonist and a κ -receptor antagonist accounting for its benefit for opioid deterrence. Buprenorphine competes with morphine and heroin for the μ receptor, but is only a partial agonist and has a "ceiling" effect. Buprenorphine was approved for treatment of opioid addiction in 2004 and is a schedule III controlled substance. Current indications include treatment of moderate to severe pain (in low doses \sim 200 μ g) and opiate addiction (in higher doses 2 to 16 mg daily). Buprenorphine is available as 2 and 8 mg tablets for sublingual administration under the brand name Subutex, and in 1 mL ampules of 0.3 mg/mL for intravenous (iv) or intramuscular (im) injection under the brand name Buprenex. For opioid addiction, the usually recommended dose is 12 to 16 mg in a single daily dose. Buprenorphine is also available in fixed combination with naloxone for sublingual administration generically and under the brand name Suboxone. Naloxone is not absorbed orally, but provides full opioid antagonism if the combination is administered intravenously, as might occur with intentional abuse. Finally, parenteral forms of buprenorphine are used for moderate to severe pain and administered iv or im, the typical dose being 0.3 mg every 6 hours as needed. Common side effects of buprenorphine include headache, dizziness, fatigue, sedation, dry mouth, urinary retention, diaphoresis and withdrawal symptoms.

Hepatotoxicity

Buprenorphine therapy has not been associated with serum enzyme elevations during treatment, although the populations studied (opioid addiction) often have coexisting chronic liver diseases which complicate such assessments. Nevertheless, rates of ALT elevations during treatment with buprenorphine (with or without naloxone) have been no greater than with comparator arms (methadone).

In addition, there have been several reports and case series of acute, clinically apparent liver injury arising within 2 to 20 weeks of starting buprenorphine, usually following misuse and intravenous administration of sublingual tablets. However, some cases occurred in patients who denied intravenous use and were on conventional sublingual doses. In most cases, the pattern of serum enzyme elevations was hepatocellular and the presentation

resembled acute toxic hepatic necrosis. Immunoallergic features (fever, rash and eosinophilia) were not present, nor were autoantibodies detected. Almost all patients with this injury had concurrent chronic hepatitis C, and several appeared to resolve the chronic infection with the acute liver injury (Case 1). Strikingly, most patients were able to continue buprenorphine without recurrence, some of whom admitted to continued intravenous abuse.

Mechanism of Injury

Buprenorphine undergoes extensive first pass hepatic extraction and is metabolized primarily by the cytochrome P450 system (CYP 3A4). The low doses used and rapid metabolism may account for its relative lack of hepatotoxicity when used in conventional doses. The appearance of an acute hepatic necrosis after intravenous injection of the sublingual tablets is likely due to direct toxicity of these high parenteral doses. The occurrence of this syndrome largely in patients with concurrent hepatitis C remains unexplained. Clearance of hepatitis C during this toxic injury raises the issue of whether the acute injury is actually due to an exacerbation of hepatitis C or whether the severe acute toxic injury can induce viral clearance.

Outcome and Management

The severity of liver injury attributed to buprenorphine has ranged from mild to severe hepatitis, and near fatal instances have been reported. Interestingly, most patients subsequently tolerated restarting buprenorphine at doses used prior to the toxic event, and some patients continued to misuse it by intravenous injection, but did not have recurrence of the liver injury.

Drug Class: [Substance Abuse Treatment Agents](#); Opioids

CASE REPORT

Case 1. Acute liver injury attributed to buprenorphine use in a patient with chronic hepatitis C.

[Modified from Case 1 in: Peyriere H, Tatern L, Bories C, Pageua G-P, Blayac J-P, Larrey D. Hepatitis after intravenous injection of sublingual buprenorphine in acute hepatitis C carriers: report of two cases of disappearance of viral replication after acute hepatitis. *Ann Pharmacother* 2009; 43: 973-7]

A 33 year old male injection drug user with chronic hepatitis C (HCV genotype 1a) developed jaundice, abdominal pain and fever shortly after injecting 3 to 5 crushed and dissolved tablets of buprenorphine (8 mg, meant for sublingual administration) intravenously. He was known to have chronic hepatitis C, but had never been treated for the infection which was considered mild. He had no other history of liver disease but consumed alcohol regularly. He took no other medications. On admission, laboratory tests showed a serum bilirubin of 29.6 mg/dL with marked elevations in serum aminotransferase levels (ALT 4132 U/L, AST 3947 U/L) and mild increases in alkaline phosphatase (347 U/L) and GGT (127 U/L; normal <50) (Table). The prothrombin index was 43% of control (INR 1.7). A transjugular liver biopsy showed panlobular necrosis, diffuse lobular inflammation, and marked cholestasis indicative of acute hepatic injury. In addition, there was moderate portal fibrosis and portal inflammation suggestive of an underlying chronic hepatitis C. Tests for hepatitis A and B and HIV were negative. Anti-HCV was present, but serum HCV RNA was present at very low levels (15 IU/mL). Jaundice resolved within a week and serum enzymes fell rapidly. Sublingual buprenorphine was restarted without a change in the pattern of recovery. In follow up 3 months later, serum ALT levels were normal and HCV RNA was undetectable. When seen almost a year later, he admitted to continuing to self-inject buprenorphine, yet serum ALT levels were still normal and HCV RNA was undetectable.

Key Points

Medication:	Buprenorphine (24 mg intravenously)
Pattern:	Hepatocellular (R=31)
Severity:	4+ (jaundice and prolongation of INR)
Latency:	Short, specific time not provided
Recovery:	Rapid, within 1-2 months
Other medications:	None

Laboratory Values

Time After Stopping	ALT (U/L)	Alk P (U/L)	Bilirubin (mg/dL)	Other
0	4132	347	29.6	Admission
2 days	2546	288	26.9	Prothrombin time 18 sec
2 weeks	132	80	2.2	Buprenorphine restarted
4 months	Normal			HCV RNA negative
10 months	11			HCV RNA negative
Normal	<40	<104	<1.2	

Comment

The clinical presentation of acute hepatic necrosis shortly after intravenous abuse of buprenorphine has been reported in several case reports and single center series of as many as 7 cases. Intriguingly, virtually all patients reported with this syndrome had a preexisting chronic hepatitis C, although many were HCV RNA negative at the time of the acute illness. The current case documents the loss of HCV RNA during the acute hepatic injury attributed to buprenorphine. Two explanations are possible. First, that the acute toxic hepatic injury caused an interruption in the replication of HCV or triggered host immune responses (the innate immune system and interferon production), resulting in clearance of hepatitis C. A second explanation is that the acute illness was due to an exacerbation of the chronic HCV infection, which led to an acute hepatitis C-like clearance of virus. The role of hepatitis C in this reaction is perhaps demonstrated best by the absence of recurrence of liver injury when buprenorphine was restarted and even when abused intravenously in high doses. The combination of buprenorphine with naloxone (a full μ opioid receptor antagonist) was developed to discourage such intravenous abuse.

PRODUCT INFORMATION

REPRESENTATIVE TRADE NAMES

Buprenorphine – Buprenex®, Generic, Subutex® (SL Tablets)

Buprenorphine/Naloxone – Suboxone®

DRUG CLASS

Substance Abuse Treatment Agents

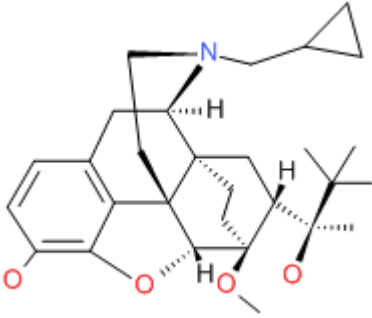
COMPLETE LABELING

Product labeling at DailyMed, National Library of Medicine, NIH

Box continues on next page...

Box continued from previous page.

CHEMICAL FORMULA AND STRUCTURE

DRUG	CAS REGISTRY NUMBER	MOLECULAR FORMULA	STRUCTURE
Buprenorphine	52485-79-7	C ₂₉ H ₄₁ N-O ₄	 The chemical structure of buprenorphine is a complex pentacyclic system. It features a morphine-like core with a partially reduced ring system. Key features include a nitrogen atom at the bridgehead position, a cyclopropylmethyl group attached to the nitrogen, and a propyl group at the 3-position. The molecule contains four oxygen atoms, with one at the 3-position and three at the 6, 7, and 8 positions. Stereochemistry is indicated with wedged and dashed bonds.

ANNOTATED BIBLIOGRAPHY

References updated: 20 May 2014

Zimmerman HJ. Hepatotoxicity: the adverse effects of drugs and other chemicals on the liver. 2nd ed. Philadelphia: Lippincott, 1999.

(Expert review of hepatotoxicity published in 1999 before the availability of buprenorphine).

Larrey D, Ripault M-P. Hepatotoxicity of psychotropic drugs and drugs of abuse. In, Kaplowitz N, DeLeve LD, eds. Drug-induced liver disease. 3rd ed. Amsterdam: Elsevier, 2013, pp. 443-62.

(Review of hepatotoxicity of drugs of abuse mentions that hepatotoxicity from buprenorphine is rare when used in recommended sublingual doses, but that severe reactions occur when used by the intravenous route, possibly as a result of mitochondrial injury).

Yaksh TL, Wallace MS. Opioids, analgesia, and pain management. In, Brunton LL, Chabner BA, Knollman BC, eds. Goodman & Gilman's the pharmacological basis of therapeutics. 12th ed. New York: McGraw-Hill, 2011, pp. 481-526.

(Textbook of pharmacology and therapeutics).

Hirschauer C, Guillemot F, Héud M, Mathieu-Chandelier C, Cortot A, Paris JC. [Is buprenorphine hepatotoxic?]. Gastroenterol Clin Biol 1989; 13: 636. French. PubMed PMID: 2753313.

(36 year old man developed abnormal liver tests 3 months after starting buprenorphine for chronic pain [bilirubin 0.6 mg/dL, ALT 100 U/L, GGT 899 U/L], resolving rapidly, but rising again on rechallenge [ALT 52 U/L]; biopsy showed steatosis and inflammation, and the patient admitted to alcohol use [50 g/day]).

Houdret N, Asnar V, Szostak-Talbodec N, Leteurtre E, Humbert L, Lecomte-Houcke M, Lhermitte M, et al. [Hepatonephritis and massive ingestion of buprenorphine]. Acta Clin Belg Suppl 1999; 1: 29-31. French. PubMed PMID: 10216978.

(33 year old man developed hepatic and renal failure 1-2 days after taking an overdose of buprenorphine [112 mg] [bilirubin 5.5 mg/dL, ALT 11,080 U/L, Alk P 334 U/L, prothrombin index 20%, creatinine 8.0 mg/dL], with subsequent rapid and complete recovery).

- Berson A, Gervais A, Cazals D, Boyer N, Durand F, Bernuau J, Marcellin P, et al. Hepatitis after intravenous buprenorphine misuse in heroin addicts. *J Hepatol* 2001; 34: 346-50. PubMed PMID: 11281569.
- (Five cases of acute hepatitis-like injury in male heroin users, ages 25-34 years, arising after 2-8 weeks of buprenorphine therapy, 4 admitted to iv injection [bilirubin 0.8-11 mg/dL, ALT 520-6595 U/L, Alk P 126-306 U/L], one with hepatic failure, rapidly resolving, but all 5 had chronic hepatitis C, one had concurrent hepatitis B and one had HIV infection; several were continued on sublingual buprenorphine without recurrence).*
- Wisniewski B, Perlemuter G, Buffet C. [Acute hepatitis following intravenous buprenorphine injection as a substitute drug in a drug-addict]. *Gastroenterol Clin Biol* 2001; 25: 328-9. French. PubMed PMID: 11395686.
- (25 year old with chronic hepatitis C and heroin use developed jaundice 72 hours after injecting buprenorphine intravenously [bilirubin 4.3 mg/dL, ALT 31 times ULN, Alk P 2.5 times ULN, HCV RNA positive], biopsy showing acute hepatitis and cholestasis; rapid recovery).*
- Petitjean S, Stohler R, Deglon JJ, Livoti S, Waldvogel D, Uehlinger C, Ladewig D. Double-blind randomized trial of buprenorphine and methadone in opiate dependence. *Drug Alcohol Depend* 2001; 62: 97-104. PubMed PMID: 11173173.
- (Controlled trial comparing methadone to buprenorphine in 58 patients with opioid dependence found poorer retention rate with buprenorphine; no hepatotoxicity reported).*
- Vidal-Trén G, Varescon I, Nabet N, Boissonnas A. Intravenous use of prescribed sublingual buprenorphine tablets by drug users receiving maintenance therapy in France. *Drug Alcohol Depend* 2003; 69: 175-81. PubMed PMID: 12609698.
- (Survey of 404 subjects on maintenance buprenorphine for opiate abuse found that 46% admitted to illicit intravenous self-administration).*
- Mattick RP, Ali R, White JM, O'Brien S, Wolk S, Danz C. Buprenorphine versus methadone maintenance therapy: a randomized double-blind trial with 405 opioid-dependent patients. *Addiction* 2003; 98: 441-52. PubMed PMID: 12653814.
- (Controlled trial in 405 patients with opioid dependence found similar rates of adverse events with buprenorphine and methadone; one patient had hepatitis C, but no other liver related adverse events reported).*
- Fudala PJ, Bridge TP, Herbert S, Williford WO, Chiang CN, Jones K, Collins J, et al; Buprenorphine/Naloxone Collaborative Study Group Office-based treatment of opiate addiction with a sublingual-tablet formulation of buprenorphine and naloxone. *N Engl J Med* 2003; 349: 949-58. PubMed PMID: 12954743.
- (Control trial of buprenorphine/naloxone vs buprenorphine alone vs placebo for 4 weeks in 326 opiate addicted patients; ALT elevations occurred in 10 patients, but 8 had concurrent hepatitis B or C).*
- Hervé, Riachi G, Noblet C, Guillement N, Tanasescu S, Gorla O, Thuillez C, et al. Acute hepatitis due to buprenorphine administration. *Eur J Gastroenterol Hepatol* 2004; 16: 1033-7. PubMed PMID: 15371928.
- (7 cases of hepatotoxicity attributed to buprenorphine, all heroin addicts, 6 men and 1 woman, ages 24 to 38 years on buprenorphine [2-12 mg/day] for 4-20 weeks, sublingual in 6 and by injection in one, all had anti-HCV and 2 HCV RNA, 2 HBsAg [ALT 9 to 68 times ULN], 5 with jaundice [bilirubin levels not given]; all recovered rapidly despite continuing buprenorphine [at reduced doses in 3]).*
- Zuin M, Giorgini A, Selmi C, Battezzati PM, Cocchi CA, Crosignani A, Benetti A, et al. Acute liver and renal failure during treatment with buprenorphine at therapeutic dose. *Dig Liver Dis* 2009; 41: e8-e10. PubMed PMID: 18294936.
- (33 year old man with chronic hepatitis C and heroin use developed jaundice 3 weeks after starting sublingual buprenorphine [20 mg daily] [bilirubin 8.4 mg/dL, ALT 300 times ULN, INR 3.1, creatinine 4.6, HCV RNA positivity], but rapid recovery and ALT levels normal and HCV RNA negative in follow-up).*

Peyriere H, Tatern L, Bories C, Pageua G-P, Blayac J-P, Larrey D. Hepatitis after intravenous injection of sublingual buprenorphine in acute hepatitis C carriers: report of two cases of disappearance of viral replication after acute hepatitis. *Ann Pharmacother* 2009; 43: 973-7. PubMed PMID: 19383935.

(Two male injection drug users, 33 and 50 years old, with chronic hepatitis C presented with jaundice after injecting buprenorphine [bilirubin 29.6 and 2.1 mg/dL, ALT 4132 and 866 U/L, Alk P 347 and 1028 U/L], resolving rapidly and associated with loss of HCV RNA: Case 1).

Orman JS, Keating GM. Buprenorphine/naloxone: a review of its use in the treatment of opioid dependence. *Drugs* 2009; 69: 577-607. PubMed PMID: 19368419.

(Review of the pharmacology, safety and efficacy of the combination of buprenorphine and naloxone as therapy of opioid dependence; no report of clinically apparent liver injury in preregistration clinical trials).

Pinto H, Maskrey V, Swift L, Rumball D, Wagle A, Holland R. The SUMMIT trial: a field comparison of buprenorphine versus methadone maintenance treatment. *J Subst Abuse Treat* 2010; 39: 340-52. PubMed PMID: 20817384.

(Patient preference controlled trial comparing buprenorphine and methadone for up to 6 months in 361 opiate dependent subjects; no discussion of hepatotoxicity or ALT elevations).

Reuben A, Koch DG, Lee WM; Acute Liver Failure Study Group. Drug-induced acute liver failure: results of a U.S. multicenter, prospective study. *Hepatology* 2010; 52: 2065-76. PubMed PMID: 20949552.

(Among 1198 patients with acute liver failure enrolled in a US prospective study between 1998 and 2007, 133 were attributed to drug induced liver injury, but none to buprenorphine or other agents used to treat substance abuse).

Vergara-Rodriguez P, Tozzi MJ, Botsko M, Nandi V, Altice F, Egan JE, O'Connor PG, et al.; BHIVES Collaborative. Hepatic safety and lack of antiretroviral interactions with buprenorphine/naloxone in HIV-infected opioid-dependent patients. *J Acquir Immune Defic Syndr* 2011; 56 Suppl 1: S62-7.

PubMed Citation (Among 141 HIV infected subjects treated with buprenorphine/naloxone for 6 months, median serum ALT and AST values did not change and no patient developed clinically apparent liver injury, 3 had transient ALT elevations during treatment [383, 123 and 218 U/L], but all resolved either spontaneously or with drug discontinuation).

Dasgupta N, Bailey EJ, Cicero T, Inciardi J, Parrino M, Rosenblum A, Dart RC. Post-marketing surveillance of methadone and buprenorphine in the United States. *Pain Med* 2010; 11:1078-91.

PubMed Citation (Between 2003 and 2007 there were increases in the rates of abuse and diversion of both methadone and buprenorphine in the US, the rates being higher for methadone).

Upadhyay A, Xueming Y. Buprenorphine-induced elevated liver enzymes in an adolescent patient. *J Child Adolesc Psychopharmacol* 2010; 20: 545-6. PubMed PMID: 21186976.

(17 year old girl developed abdominal pain and enzyme elevations 9 days after starting buprenorphine with naloxone [bilirubin normal, ALT 452 U/L, anti-HCV negative], resolving rapidly on stopping; also taking quetiapine and tizanidine).

Bogenschutz MP, Abbott PJ, Kushner R, Tonigan JS, Woody GE. Effects of buprenorphine and hepatitis C on liver enzymes in adolescents and young adults. *J Addict Med* 2010; 4: 211-6. PubMed PMID: 21170166.

(Among 152 patients with opioid dependence treated with 2 vs 12 weeks of buprenorphine with naloxone, ALT elevations occurred in 13% vs 23% of patients, but were mostly attributed to underlying HCV infection).

Kraus ML, Alford DP, Kotz MM, Levounis P, Mandell TW, Meyer M, Salsitz EA, et al. Statement of the American Society of Addiction Medicine Consensus Panel on the Use of Buprenorphine in Office-Based Treatment of Opioid Addiction. *J Addict Med* 2011; 5: 254-263. PubMed PMID: 22042215.

(Guidelines and recommendations for use of buprenorphine in office based practice; no discussion of hepatotoxicity).

Steiner DJ, Sitar S, Wen W, Sawyerr G, Munera C, Ripa SR, Landau C. Efficacy and safety of the seven-day buprenorphine transdermal system in opioid-naïve patients with moderate to severe chronic low back pain: an enriched, randomized, double-blind, placebo-controlled study. *J Pain Symptom Manage* 2011; 42: 903-17 PubMed PMID: 21945130.

(541 patients with severe low back pain were randomized to receive transdermal buprenorphine or placebo for 12 weeks; overall, clinical laboratory test results did not change on buprenorphine treatment).

Amass L, Pukeleviciene V, Subata E, Almeida AR, Pieri MC, D'Egidio P, Stankova Z, et al. A prospective, randomized, multicenter acceptability and safety study of direct buprenorphine/naloxone induction in heroin-dependent individuals. *Addiction* 2012; 107: 142-51. PubMed PMID: 21749526.

(Among 187 injection drug users treated for 4 weeks with buprenorphine with naloxone, common side effects included insomnia, sweating, nausea and anxiety, but all serious adverse events were considered unrelated; no mention of ALT elevations).

Ray R, Vaswani M, Deb KS, Sethi H, Chopra A, Kishore N, Goyal R. Post marketing surveillance of sublingual buprenorphine naloxone combination tablets. *Indian J Physiol Pharmacol* 2012; 56: 359-66. PubMed PMID: 23781656.

(Among 158 patients with opioid dependence treated with buprenorphine with naloxone, liver enzyme elevations were reported in 52% of patients, but none was associated with severe hepatitis).

Saxon AJ, Ling W, Hillhouse M, Thomas C, Hasson A, Ang A, Doraimani G, et al. Buprenorphine/Naloxone and methadone effects on laboratory indices of liver health: a randomized trial. *Drug Alcohol Depend* 2013; 128: 71-6. PubMed PMID: 22921476.

(Among 731 patients with opioid dependency treated with either buprenorphine with naloxone or methadone for at least 24 weeks, 12.6% vs 17.9% developed ALT elevations [>2 times ULN], which were "extreme" in only 2.1% vs 3.6% [bilirubin 0.7-3.7 mg/dL, ALT 418-6280 U/L], usually attributable to underlying HBV or HCV infection, but specific details were not provided).